


PATIENT PRESENTING CLINICAL SIGNS

Shadow Kolodziej History: Shunt hunt. Elevated bile acids pre and post >200 Hx of previous nephrectomy.
 Abnormal PE/Chem/CBC/UA Results:

SPECIES COMPUTED TOMOGRAPHIC STUDY OF THE ABDOMEN

Canine A high resolution pre- and post-contrast CT study of the abdomen is provided for review.

BREED COMPUTED TOMOGRAPHIC FINDINGS

Miniature Schnauzer The serosal fat presents normal attenuation behavior. There is no evidence of peritoneal effusion or peritonitis.

SEX

Neutered Male The volume of the left kidney is moderately increased and presents within normal limits for shape and organ architecture. After contrast administration a physiological nephro- and pyelogram is noted. The right kidney is absent. A small amount of sedimented mineral attenuating material is appreciated on the ventral urinary bladder wall.

AGE

15 Months The adrenal glands are within normal limits for size, shape and organ architecture. The spleen presents with normal shape, even surface, uniformly attenuating parenchyma and homogeneous contrast enhancement, unremarkable.

INTERPRETED BY

Sebastian Schaub, DVM
 Dr. med. vet. DipECVDI

The hepatic volume is mildly decreased. The hepatic parenchyma is uniform soft tissue attenuating and contrast enhancing.

HOSPITAL NAME

Mobiel Pet Imaging

The right gastric vein is significantly dilated and can be appreciated along the minor curvature of the stomach. Originating from the dilated right gastric vein, approximately level with the dorsal aspect of the fundus of the stomach, a short anomalous vascular loop is coursing medially draining into the caudal vena cava from the left, cranial to the left renal vein; the anomalous vascular loop is measuring 6.0 mm in diameter. The intrahepatic portal vessels can be appreciated up to the third order vessels. The pancreas is evenly contoured, the pancreatic parenchyma is homogeneous and presents uniform contrast enhancement.

REFERRING VET

Dr. Meaux

The position, delineation, wall and content of the gastrointestinal tract are considered within normal limits throughout.

INVOICE

17625

The bony and surrounding soft tissue structures reveal no abnormalities.

COMPUTED TOMOGRAPHIC DIAGNOSIS
DATE

10/7/22

- Single congenital extrahepatic portosystemic shunt, right gastric vein to caudal vena cava (right gastric shunt)
- Mild microhepatica



PATIENT

Shadow Kolodziej

- Left sided renomegaly
- History of right sided nephrectomy
- Mild bladder sand

SPECIES

Canine

BREED

Miniature Schnauzer

SEX

Neutered Male

AGE

15 Months

INTERPRETED BY

Sebastian Schaub, DVM
Dr. med. vet. DipECVDI

HOSPITAL NAME

Mobiel Pet Imaging

REFERRING VET

Dr. Meaux

INVOICE

17625

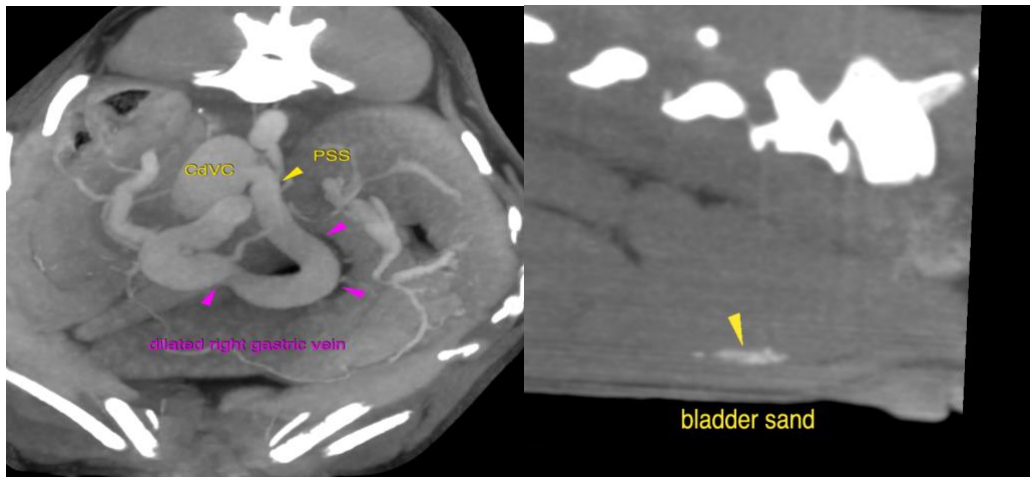
DATE

10/7/22

INTERPRETATION OF THE FINDINGS & FURTHER RECOMMENDATIONS

The current CT study is consistent with a congenital single extrahepatic portosystemic shunt (right gastric vein to caudal vena cava). Secondary mild microhepatica and bladder sand.

Surgical intervention by a slow progressive closure technique (ameroid constrictor, cellophane banding) is the therapy of choice. Ligation of the shunt vessel may be feasible as well if there is no evidence of portal hypertension during digital compression of the shunting vessel. Empirical treatment until surgery along with feeding of a hepatic diet is recommended.



The information and recommendations provided are based on the images presented by the referring veterinarian/sonographer. No evaluation can be communicated regarding pathology that was not visible in the image/video clips provided.

Thank you for this referral. If the clinical or image interpretation does not parallel your findings or if I can be of any further assistance please contact me.

Sebastian Schaub, Sebastian Schaub, DVM, Dr. med. vet. DipECVDI
sebast.schaub@gmail.com



PATIENT

Shadow Kolodziej

SPECIES

Canine

BREED

Miniature Schnauzer

SEX

Neutered Male

AGE

15 Months

INTERPRETED BY

Sebastian Schaub, DVM
Dr. med. vet. DipECVDI

HOSPITAL NAME

Mobiel Pet Imaging

REFERRING VET

Dr. Meaux

INVOICE

17625

DATE

10/7/22