

**PATIENT PRESENTING CLINICAL SIGNS**

Nova Depaz History: Surgical planning for ovarian remnant.

COMPUTED TOMOGRAPHIC STUDY OF THE ABDOMEN**SPECIES**

Canine

A high resolution pre- and post-contrast CT study of the abdomen is provided for review.

COMPUTED TOMOGRAPHIC FINDINGS**BREED**

Australian Shepherd

The serosal fat presents normal attenuation behavior. There is no evidence of peritoneal effusion or peritonitis.

SEX

Female

Both kidneys present within normal limits for size, shape and organ architecture. After contrast administration a bilaterally symmetric and uniform nephro- and pyelogram is noted.

Caudal to the left kidney, an ovary with corpora lutea/follicles is appreciated, measuring approximately 2 cm in size. The right ovary is absent. The vagina is prominent.

AGE

1 Year 3 Months

The adrenal glands are within normal limits for size, shape and organ architecture.

Both liver and spleen present with normal shape, even surface, uniformly attenuating parenchyma and homogeneous contrast enhancement, unremarkable.

INTERPRETED BY

Sebastian Schaub, DVM
Dr. med. vet. DipECVDI

The portal vein presents a normal order of its tributary veins and intrahepatic branching. No abnormal vessel is noted inside and outside of the liver parenchyma.

The pancreas is evenly contoured, the pancreatic parenchyma is homogeneous and presents uniform contrast enhancement.

HOSPITAL NAME

Mobile Pet Imaging

The position, delineation, wall and content of the gastrointestinal tract are considered within normal limits throughout.

The bony and surrounding soft tissue structures reveal no abnormalities.

REFERRING VET

Dr. Meaux

COMPUTED TOMOGRAPHIC DIAGNOSIS

- Left sided ovarian remnant syndrome
- Hyperplastic vagina due to estrous cycle

INVOICE

17624

INTERPRETATION OF THE FINDINGS & FURTHER RECOMMENDATIONS

The CT study presents a retained left ovaria ± short cranial segment of the left uterine horn.

DATE

10/7/22



PATIENT

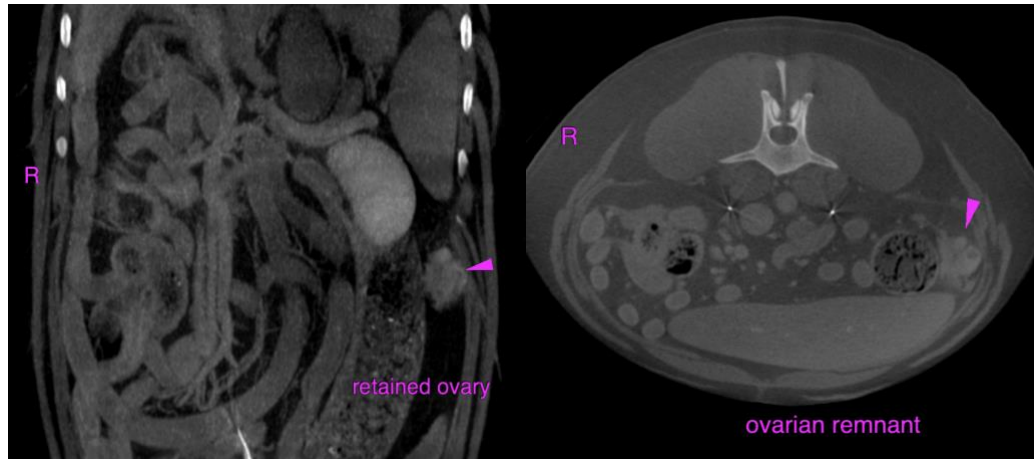
Nova Depaz

SPECIES

Canine

BREED

Australian Shepherd



SEX

Female

The information and recommendations provided are based on the images presented by the referring veterinarian/sonographer. No evaluation can be communicated regarding pathology that was not visible in the image/video clips provided.

AGE

1 Year 3 Months

Thank you for this referral. If the clinical or image interpretation does not parallel your findings or if I can be of any further assistance please contact me.

Sebastian Schaub, Sebastian Schaub, DVM, Dr. med. vet. DipECVDI
sebast.schaub@gmail.com

INTERPRETED BY

Sebastian Schaub, DVM
Dr. med. vet. DipECVDI

HOSPITAL NAME

Mobile Pet Imaging

REFERRING VET

Dr. Meaux

INVOICE

17624

DATE

10/7/22