



**PATIENT PRESENTING CLINICAL SIGNS**

**Gunnarr Potthoff** History: Gunnarr was diagnosed with aspiration pneumonia for the second time on 9/16/22. His first time being diagnosed was on 6/1/22. Gunnar has been improving but still has a residual cough. Owners have been injecting 2.8mls Meropenem SQ every 12 hours since 10/5/22. Gunnarr was prescribed Simplicef 200mg SID at his appointment today.

**SPECIES**

Canine Abnormal PE/Chem/CBC/UA Results: BAR, heart and lungs good, has "chuff" in clinic - sounds like clearing of throat.

**BREED RADIOGRAPHIC STUDY OF THE THORAX**

Weimaraner Radiographs of the thorax in three imaging planes are provided for review.

**SEX RADIOGRAPHIC FINDINGS**

Neutered Male In comparison to the preceding radiographic study the lung parenchymal presents with a generalized progressive unstructured reticular pattern, mildly accentuated in the cranioventral aspects of the lung. The remainder of the thoracic structures present without additional findings.

**AGE RADIOGRAPHIC DIAGNOSIS**

10 Years 11 Months

- Generalized moderate unstructured interstitial lung pattern, accentuated in the cranioventral aspects of the lung, progressive compared to the previous radiographic study

**INTERPRETED BY**

Sebastian Schaub,  
DVM Dr. med. vet.  
DipECVDI

**INTERPRETATION OF THE FINDINGS & FURTHER RECOMMENDATIONS**

The pulmonary pattern is progressive in comparison to the previous radiographic study and given the increased radiopacity of the cranioventral aspects of the lung parenchyma the findings are suggestive for emerging or resolving pneumonia. Consider complementing workup by blood work to screen for inflammatory changes (e.g. leukocytosis, elevated crp).

**HOSPITAL NAME**

Elizabeth AH

No abnormality can be specified, explaining the recurrent courses of pneumonia.

**REFERRING VET**

Kim Allyn, DVM

**INVOICE**

17627

**DATE**

10/7/22



**PATIENT**

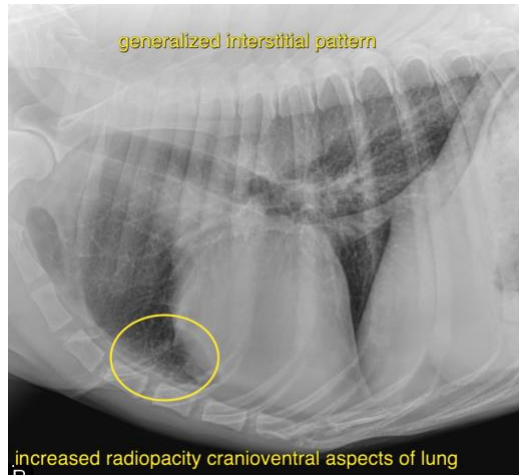
Gunnarr Potthoff

**SPECIES**

Canine

**BREED**

Weimaraner



**SEX**

Neutered Male

**The information and recommendations provided are based on the images presented by the referring veterinarian/sonographer. No evaluation can be communicated regarding pathology that was not visible in the image/video clips provided.**

**AGE**

10 Years 11 Months

Thank you for this referral. If the clinical or image interpretation does not parallel your findings or if I can be of any further assistance please contact me.

**Sebastian Schaub**, Sebastian Schaub, DVM, Dr. med. vet. DipECVDI  
sebast.schaub@gmail.com

**INTERPRETED BY**

Sebastian Schaub,  
DVM Dr. med. vet.  
DipECVDI

**HOSPITAL NAME**

Elizabeth AH

**REFERRING VET**

Kim Allyn, DVM

**INVOICE**

17627

**DATE**

10/7/22