



PATIENT PRESENTING CLINICAL SIGNS

Roxy Day History: Mass right hock previously diagnosed as synovial cyst . Biopsy performed revealing synovial lipomyxoma, tentative partial right hindlimb amputation CT of thorax/abdomen only for pre-op staging

SPECIES Abnormal PE/Chem/CBC/UA Results:

Canine COMPUTED TOMOGRAPHIC STUDY OF THE THORAX AND ABDOMEN

BREED A pre- and post-contrast CT study of the thorax and abdomen in a soft tissue and bone reconstruction are provided for review.

Rottweiler COMPUTED TOMOGRAPHIC FINDINGS

SEX Thorax

Spayed Female The bony and surrounding soft tissue structures are within normal limits.

AGE The sternal, cranial mediastinal and tracheobronchial lymph nodes are small elongated with a normal short-to-long-axis-ratio is < 0.5, the attenuation and contrast enhancement pattern is uniform and considered within normal limits.

4 Years The cardiovascular structures including the pulmonary vasculature are within normal limits.

INTERPRETED BY The bronchial tree presents with regular branching and tapers uniformly towards the periphery as expected, the bronchial walls are thin and smooth. The bronchus-to-artery ratio is within normal limits.

Sebastian Schaub, DVM Dr. med. vet. DipECVDI The lung parenchyma presents the expected architecture and attenuation behavior.

Small incidental gas pockets are seen within the esophageal lumen, there is no evidence of abnormal dilation.

HOSPITAL NAME

Animal Health Partners Abdomen

The serosal fat presents normal attenuation behavior. There is no evidence of peritoneal effusion or peritonitis.

REFERRING VET

Dr. Debbie Reynolds Both kidneys present within normal limits for size, shape and organ architecture. After contrast administration a bilaterally symmetric and uniform nephro- and pyelogram is noted.

The adrenal glands are within normal limits for size, shape and organ architecture.

INVOICE

13599 Both liver and spleen present with normal shape, even surface, uniformly attenuating parenchyma and homogeneous contrast enhancement, unremarkable.

DATE

10/7/21



PATIENT The pancreas is evenly contoured, the pancreatic parenchyma is homogeneous and presents uniform contrast enhancement.

Roxy Day

The position, delineation, wall and content of the gastrointestinal tract are considered within normal limits throughout.

SPECIES

Canine

The right medial iliac lymph node is prominent, uniform soft tissue attenuating and mild heterogeneous contrast enhancing; measuring 16 x 7 x 30 mm in size.

Mild peripheral mineralization of the dural tube is noted. The left coxofemoral joint presents mild to moderate osteophyte new bone formation.

BREED

Rottweiler

COMPUTED TOMOGRAPHIC DIAGNOSIS

- Lymphadenopathy right medial iliac lymph node
- Mild degenerative osteoarthritis left coxofemoral joint
- Structural normal thorax, no evidence of pulmonary metastatic disease
- Incidental mild dural mineralization

SEX

Spayed Female

INTERPRETATION OF THE FINDINGS & FURTHER RECOMMENDATIONS

AGE

4 Years

The odds for reactive hyperplasia of the right medial iliac lymph node are high. However, ultrasound guided FNA sampling is recommended to rule out metastatic spread.

INTERPRETED BY

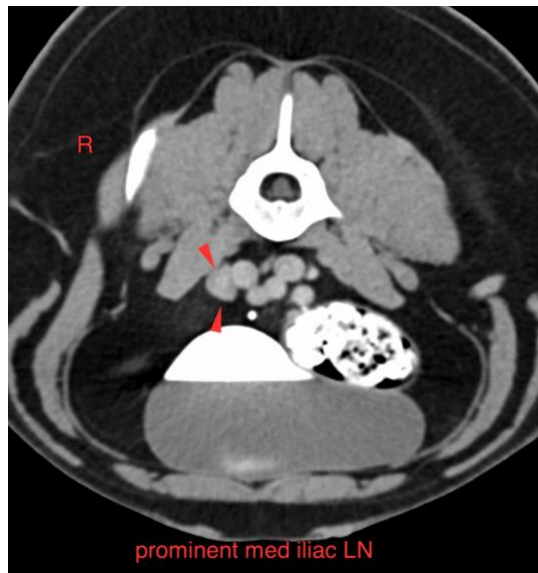
Sebastian Schaub,
DVM Dr. med. vet.
DipECVDI

HOSPITAL NAME

Animal Health
Partners

REFERRING VET

Dr. Debbie Reynolds



INVOICE

13599

The information and recommendations provided are based on the images presented by the referring veterinarian. No evaluation can be communicated regarding pathology that was not visible in the image/video clips provided.

DATE

10/7/21



PATIENT

Roxy Day

Thank you for this referral. If the clinical or image interpretation does not parallel your findings or if I can be of any further assistance please contact me.

SPECIES

Canine

Sebastian Schaub, Sebastian Schaub, DVM, Dr. med. vet. DipECVDI
sebast.schaub@gmail.com

BREED

Rottweiler

SEX

Spayed Female

AGE

4 Years

INTERPRETED BY

Sebastian Schaub,
DVM Dr. med. vet.
DipECVDI

HOSPITAL NAME

Animal Health
Partners

REFERRING VET

Dr. Debbie Reynolds

INVOICE

13599

DATE

10/7/21