



PATIENT PRESENTING CLINICAL SIGNS

Eric Nuttall History: Head shaking, some loss of hearing. Narrowing and discomfort of external ear canal and possible middle ear

SPECIES Abnormal PE/Chem/CBC/UA Results: ALB slightly raised

Canine **COMPUTED TOMOGRAPHIC STUDY OF THE SKULL**

A high resolution pre- and post-contrast CT study of the skull is provided for review.

BREED **COMPUTED TOMOGRAPHIC FINDINGS**

Chihuahua The tooth elements 105, 107, 205, 207, 305, 306 and 405 are absent.

SEX The nasal cavity presents the expected aerated spaces between thin and even conchae and turbinates with smooth mucosal lining. A moderate left sided deviation of the nasal septum is seen as a anatomical variant.
Male

AGE Both temporomandibular joints present congruent joint spaces with even subchondral bone surfaces and are considered within normal limits.

7 Years Both tympanic bullae are aerated, the mucosal lining is not seen, the bony wall is smooth and thin. The external ear canals are within normal limits.

INTERPRETED BY The brain presents no deviation from normal anatomy and symmetry. The brain parenchyma is homogeneous and within normal limits for attenuation and distribution of contrast enhancement. The ventricular system is non-dilated and symmetric.
Sebastian Schaub, DVM Dr. med. vet. DipECVDI

HOSPITAL NAME The submandibular and medial retropharyngeal lymph nodes are small and elongated with a normal short-to-long-axis-ratio is < 0.5, the attenuation and contrast enhancement pattern is uniform.

Myerscough VG **COMPUTED TOMOGRAPHIC DIAGNOSIS**

- Multiple absent teeth
- Normal middle and inner ear
- Normal external ear canals

REFERRING VET **INTERPRETATION OF THE FINDINGS & FURTHER RECOMMENDATIONS**

Julie Bettess

INVOICE The CT study of the skull presents without clinically relevant abnormalities. There are no signs for otitis media or overt otitis externa – the latter has to be correlated with the findings of the clinical examination.
13597

DATE

10/7/21



PATIENT

Eric Nuttall

SPECIES

Canine

BREED

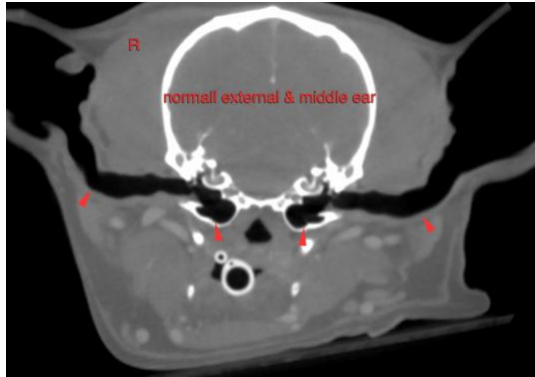
Chihuahua

SEX

Male

AGE

7 Years



The information and recommendations provided are based on the images presented by the referring veterinarian. No evaluation can be communicated regarding pathology that was not visible in the image/video clips provided.

Thank you for this referral. If the clinical or image interpretation does not parallel your findings or if I can be of any further assistance please contact me.

Sebastian Schaub, Sebastian Schaub, DVM, Dr. med. vet. DipECVDI
sebast.schaub@gmail.com

INTERPRETED BY

Sebastian Schaub,
DVM Dr. med. vet.
DipECVDI

HOSPITAL NAME

Myerscough VG

REFERRING VET

Julie Bettess

INVOICE

13597

DATE

10/7/21