



PATIENT

Sofie Gustafson

PRESENTING CLINICAL SIGNS

She hurt he self around 10am this morning. They are not sure what happened. Greg heard her yelp going up the stairs then she was fine and followed Echo up the stairs and tried to jump on the bed and couldn't do it and yelped. They gave her some baby aspirin went down stairs again. Sophie then sat by Echo and started to shake and pant heavily. Now it hurts her to even get up. Abnormal PE/Chem/CBC/UA Results: Relatively normal exam other than severe response to mid back palpation and deep spinal palpation. Severe pain to any movement of the rear legs. Caudal no deep pain reaction but spinal reflex is intact. Tail still mobile.

SPECIES

Canine

BREED

English Mastiff Mix

RADIOGRAPHIC STUDY OF THE THORACIC & LUMBAR SPINE

Radiographs of the thoracic & lumbar spine in two orthogonal imaging planes are provided for review.

SEX

Spayed

RADIOGRAPHIC FINDINGS

The osseous and surrounding soft tissue structures of the thoracic spine are within normal limits. The vertebral endplates L3/L4 present moderate spondylosis formation and the respective intervertebral disc space is mildly narrowed.

AGE

9 Years, 6 Months

The remainder of the osseous and soft tissue structures of the lumbar spine are within normal limits.

INTERPRETED BY

Sebastian Schaub, DVM
Dr. med. vet. DipECVDI

- Chronic discopathy L3/L4
- Normal thoracic spine

INTERPRETATION OF THE FINDINGS & FURTHER RECOMMENDATIONS

There is evidence of chronic disc disease L3/L4 with degenerative changes along the endplates – discopathy might or might not be associated with compressive myelopathy.

HOSPITAL NAME

Elizabeth Animal Hospital

No additional abnormalities of the spine are appreciated.

REFERRING VET

Leon Anderson, DVM

INVOICE

54513

DATE

10-6-22



PATIENT

Sofie Gustafson

SPECIES

Canine

BREED

English Mastiff Mix

SEX

Spayed

AGE

9 Years, 6 Months

INTERPRETED BY

Sebastian Schaub, DVM
Dr. med. vet. DipECVDI

HOSPITAL NAME

Elizabeth Animal
Hospital

REFERRING VET

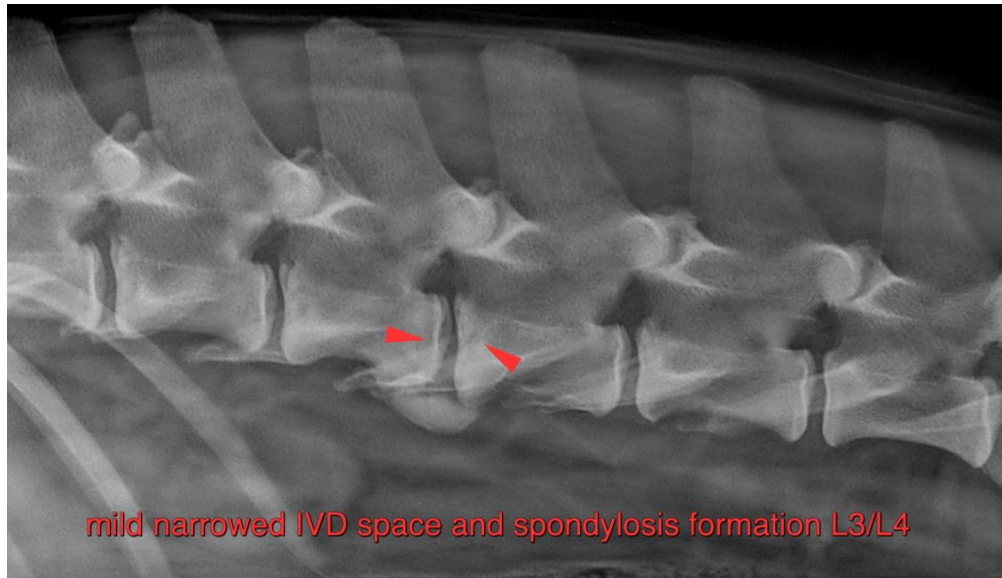
Leon Anderson, DVM

INVOICE

54513

DATE

10-6-22



The information and recommendations provided are based on the images presented by the referring veterinarian/sonographer. No evaluation can be communicated regarding pathology that was not visible in the image/video clips provided.

Thank you for this referral. If the clinical or image interpretation does not parallel your findings or if I can be of any further assistance please contact me.

Sebastian Schaub, Sebastian Schaub, DVM, Dr. med. vet. DipECVDI
sebast.schaub@gmail.com