



PATIENT PRESENTING CLINICAL SIGNS

PATIENT
Oakley Masolini

SPECIES
Canine

BREED
Beagle

lethargic, Throwing up and Diarrhea since last night- hasn't thrown up since this morning, seems uncomfortable to lay down kind of tender on the l side- seems a little bloated- could have eaten something in the back yard but wouldn't know what- no changes to food or treats or anything ; ate in AM yesterday, was fine during day, didn't want to eat in PM, not able to keep any water down and not eating; initial vomiting had brown tint 830-900pm last night, last V was clear/mucousy about 700am today; bloody diarrhea also started last night, most recent large volume bloody mucousy diarrhea 9am today. O rpts stomach rumbling alot
Abnormal PE/Chem/CBC/UA Results: PE findings: lethargic, sl dehydrated, sl delayed CRT, mm pink, HR 120, RR 32, T 99.8, abdom sl tense/painful but no obvious masses or organomegally Slight increased neutrophils 14.99, inc rbc 10.06, inc hgb 23.7, inc hct 67.4, inc alb 4.5, inc amy 1244,. inc glu 141, CPL 267 (suspected range 200-400), fecal float neg, giardia neg, fecal cytology rod overgrowth, Cortisol level pending

SEX RADIOGRAPHIC STUDY OF THE ABDOMEN

SEX
MN
Radiographs of the abdomen three imaging planes are provided for review.

AGE RADIOGRAPHIC FINDINGS

AGE
3 Years, 10 Months
The surrounding bony structures are within normal limits.
No abnormalities of the extraabdominal soft tissues are noted. The abdominal wall is smooth and thin.

INTERPRETED BY
The serosal detail is maintained throughout the peritoneal and retroperitoneal space.

Sebastian Schaub, DVM
Dr. med. vet. DipECVDI
The liver is appropriate in position, size and presents uniform opacity.

The splenic head is in the anticipated position and within normal limits for size and opacity. The splenic body and tail are considered normal for position, size, shape and opacity.

HOSPITAL NAME
Family Pet Veterinary Center
Both kidneys are seen and present with normal size, shape, delineation and opacity. The urinary bladder is in its anticipated position. No radiopaque calculi are noted throughout the upper and lower urinary tract.

The stomach is in its anticipated position and is mild to moderately distended by gas and fluid .

REFERRING VET
The small intestinal loops are of even diameter and non-dilated, a small amount of gas is seen within the small intestinal loops and considered within normal limits.

Ryan Southard
The colon is seen in the expected position and contains a small amount of unformed fecal material.

INVOICE RADIOGRAPHIC DIAGNOSIS

- 54468
- Gas and fluid filled stomach
 - Unformed fecal material in colon

DATE INTERPRETATION OF THE FINDINGS & FURTHER RECOMMENDATIONS

10-6-22
The radiographic changes in combination with the clinical signs are highly suggestive for gastroenteritis/acute hemorrhagic diarrhea syndrome. There is no evidence of radiopaque foreign material or signs for gastrointestinal mechanical obstruction. If clinical signs are refractory to therapy, recommend follow up radiographs or a complete abdominal ultrasound



PATIENT

Oakley Masolini

examination; in some cases a high ileus may lack classical radiographic signs of mechanical obstruction.

SPECIES

Canine

BREED

Beagle

SEX

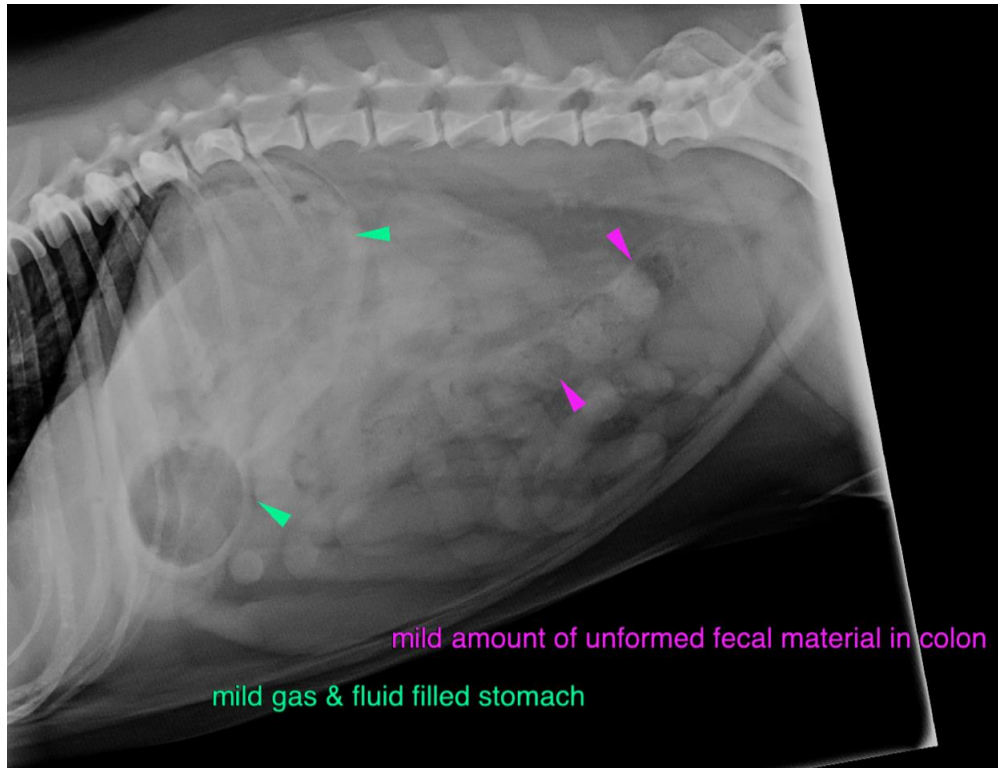
MN

AGE

3 Years, 10 Months

INTERPRETED BY

Sebastian Schaub, DVM
Dr. med. vet. DipECVDI



HOSPITAL NAME

Family Pet Veterinary
Center

The information and recommendations provided are based on the images presented by the referring veterinarian/sonographer. No evaluation can be communicated regarding pathology that was not visible in the image/video clips provided.

REFERRING VET

Ryan Southard

Thank you for this referral. If the clinical or image interpretation does not parallel your findings or if I can be of any further assistance please contact me.

Sebastian Schaub, Sebastian Schaub, DVM, Dr. med. vet. DipECVDI
sebast.schaub@gmail.com

INVOICE

54468

DATE

10-6-22