



**PATIENT**

Chleo Lena

**PRESENTING CLINICAL SIGNS**

Vomiting since Sept 30 after licking baby shampoo. Last vomited 3x today as per O. BW shows normal kidney and live value with low WBC and neutrophils. Diarrhea as of today on exam. O stated solid stool as of yesterday. No linear FB under the tongue R/O Obstruction or any abnormalities

**SPECIES**

Feline

**RADIOGRAPHIC STUDY OF THE ABDOMEN**

Radiographs of the abdomen in three imaging planes are provided for review.

**BREED**

Simese

**RADIOGRAPHIC FINDINGS**

The surrounding bony structures are within normal limits, the growth plates are age related open. No abnormalities of the extraabdominal soft tissues are noted. The abdominal wall is smooth and thin.

**SEX**

Female

The serosal detail is maintained throughout the peritoneal and retroperitoneal space.

**AGE**

7 Months

The liver is appropriate in position, size and presents uniform opacity.

The splenic head is in the anticipated position and within normal limits for size and opacity. The splenic body and tail are considered normal for position, size, shape and opacity.

Both kidneys are seen and present with normal size, shape, delineation and opacity. The urinary bladder is in its anticipated position. No radiopaque calculi are noted throughout the upper and lower urinary tract.

**INTERPRETED BY**

Sebastian Schaub, DVM  
Dr. med. vet. DipECVDI

The stomach is in its anticipated position and is empty.

The small intestinal loops are of even diameter and non-dilated, multiple small intestinal loops contain foamy soft tissue material.

**HOSPITAL NAME**

Truscott Animal  
Hospital

The colon is seen in the expected position and contains a small amount of fecal material and is moderately distended by gas.

**RADIOGRAPHIC DIAGNOSIS**

- Mild foamy gas pattern small intestinal loops
- Gas distended colon

**REFERRING VET**

Dr. Medhat Meawad

**INTERPRETATION OF THE FINDINGS & FURTHER RECOMMENDATIONS**

The radiographic study presents no specific abnormality, explaining the presenting clinical signs, given the mild foamy gas pattern of the small intestinal loops and the presenting clinical signs the presumptive diagnosis is gastritis/gastroenteritis. There is no evidence of radiopaque foreign material or signs for gastrointestinal mechanical obstruction. If clinical signs are refractory to therapy, recommend follow up radiographs or a complete abdominal ultrasound examination; in some cases a high ileus may lack classical radiographic signs of mechanical obstruction. Rule out other potentials such as parasitic infection, dietary indiscretion, dysbacteriosis.

**INVOICE**

54482

**DATE**

10-6-22



**PATIENT**

Chleo Lena

**SPECIES**

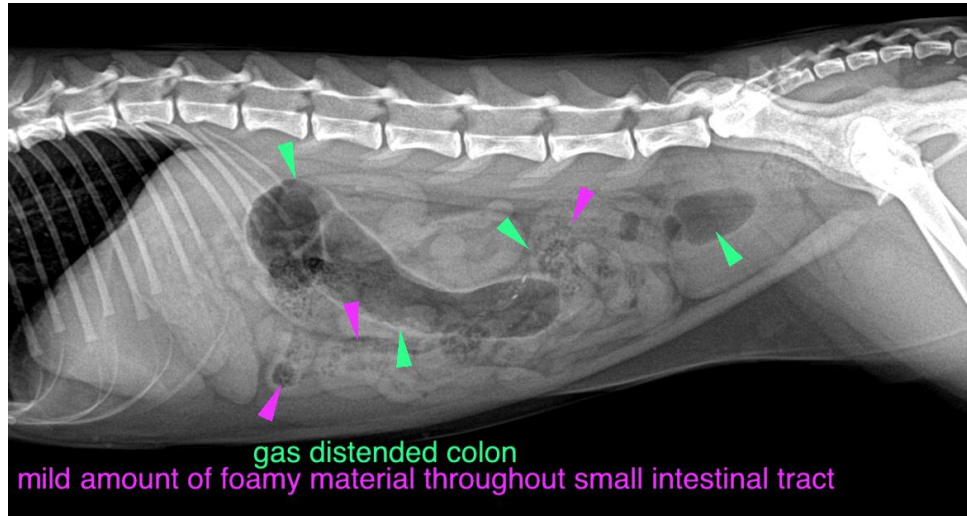
Feline

**BREED**

Siamese

**SEX**

Female



**AGE**

7 Months

The information and recommendations provided are based on the images presented by the referring veterinarian/sonographer. No evaluation can be communicated regarding pathology that was not visible in the image/video clips provided.

**INTERPRETED BY**

Sebastian Schaub, DVM  
Dr. med. vet. DipECVDI

Thank you for this referral. If the clinical or image interpretation does not parallel your findings or if I can be of any further assistance please contact me.

**Sebastian Schaub**, Sebastian Schaub, DVM, Dr. med. vet. DipECVDI  
sebast.schaub@gmail.com

**HOSPITAL NAME**

Truscott Animal  
Hospital

**REFERRING VET**

Dr. Medhat Meawad

**INVOICE**

54482

**DATE**

10-6-22