



PATIENT

Bosco Dohrmann

PRESENTING CLINICAL SIGNS

Chronic upper respiratory noise and stridor. Previously responsive to steroids and antibiotic treatment.

Abnormal PE/Chem/CBC/UA Results: Chem/CBC/SDMA/T4 all WNL

SPECIES

Feline

COMPUTED TOMOGRAPHY OF THE SKULL

A high resolution plain CT study of the skull is provided for review.

BREED

DLH

COMPUTED TOMOGRAPHIC FINDINGS

Multiple teeth are absent.

The right nasal cavity is occupied by soft tissue attenuating material. The right maxillary and nasal bone present moth eaten osteolytic lesions and lysis with perforation of the cribriform plate is noted. The choana are obliterated by soft tissue material.

SEX

MN

Both temporomandibular joints present congruent joint spaces with even subchondral bone surfaces and are considered within normal limits.

AGE

15 Years

Both tympanic bullae are aerated, the mucosal lining is not seen, the bony wall is smooth and thin. The external ear canals are within normal limits.

The submandibular and medial retropharyngeal lymph nodes are small and elongated with a normal short-to-long-axis-ratio is < 0.5, the attenuation and contrast enhancement pattern is uniform.

INTERPRETED BY

Sebastian Schaub, DVM
Dr. med. vet. DipECVDI

COMPUTED TOMOGRAPHIC DIAGNOSIS

- Right nasal soft tissue mass with polyostotic semiaggressive osteolytic lesions of the associated osseous structures and perforation of the cranial fossa
- Multiple absent teeth

HOSPITAL NAME

State Avenue Vet
Clinic

INTERPRETATION OF THE FINDINGS & FURTHER RECOMMENDATIONS

The right nasal mass presents with aggressive bone lesion, increasing the odds for primary nasal neoplasia – such as lymphosarcoma, adenocarcinoma, squamous cell carcinoma, transitional cell carcinoma, other. However, inflammatory nasal polypoid lesion, granulomatous nasal disease or less likely rhinitis are potentials. Rhinoscopy including biopsy can be used as advanced diagnostic tests.

REFERRING VET

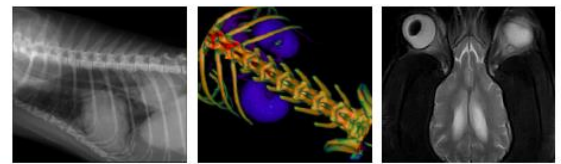
Dr. Jessie Evoniuk

INVOICE

54490

DATE

10-6-22



PATIENT

Bosco Dohrmann

SPECIES

Feline

BREED

DLH

SEX

MN

AGE

15 Years

INTERPRETED BY

Sebastian Schaub, DVM
Dr. med. vet. DipECVDI

HOSPITAL NAME

State Avenue Vet
Clinic

REFERRING VET

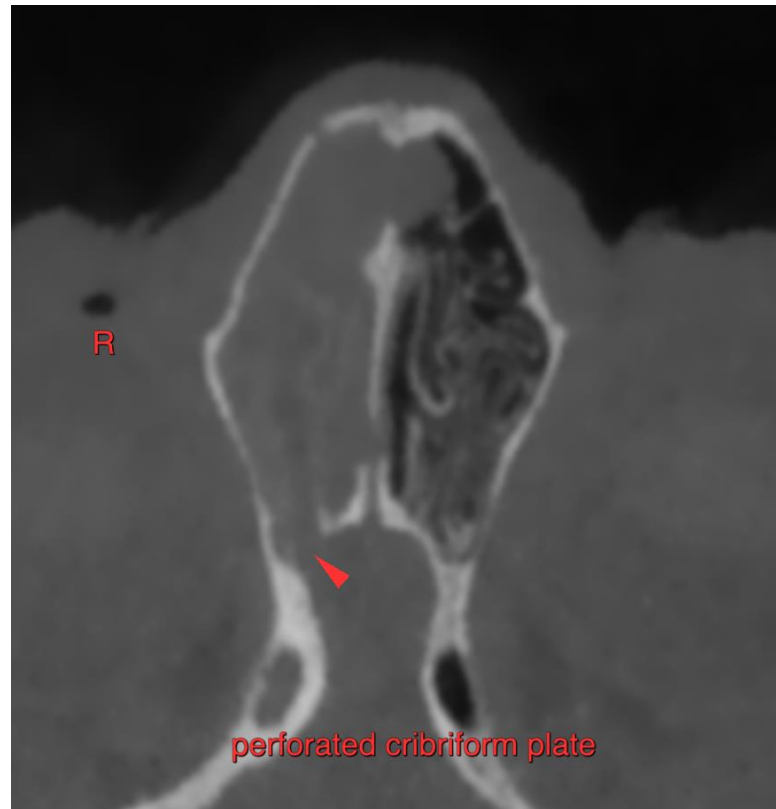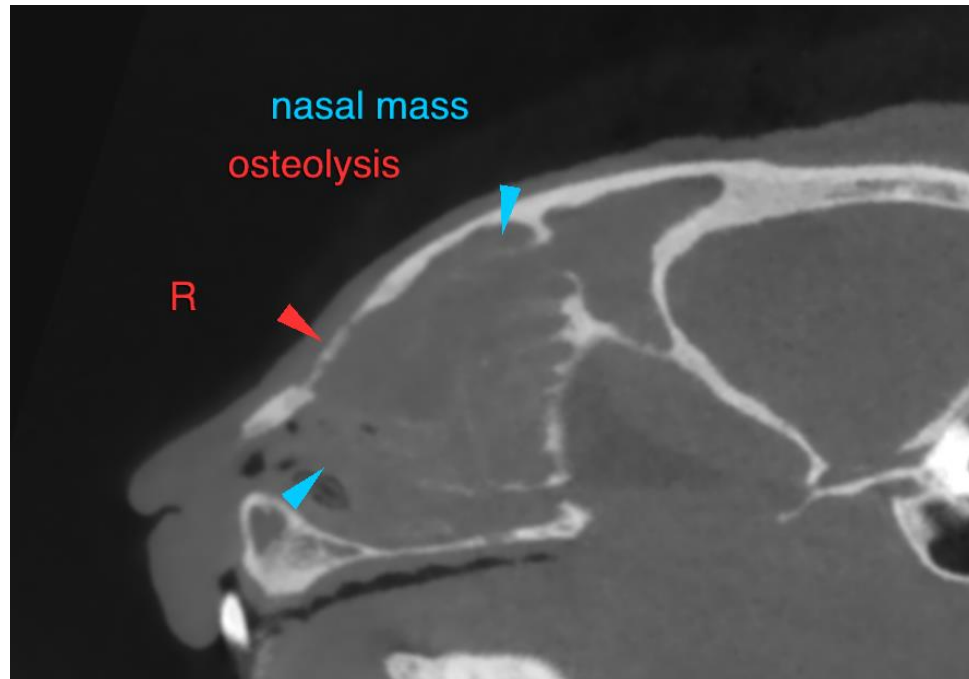
Dr. Jessie Evoniuk

INVOICE

54490

DATE

10-6-22





PATIENT

Bosco Dohrmann

SPECIES

Feline

The information and recommendations provided are based on the images presented by the referring veterinarian/sonographer. No evaluation can be communicated regarding pathology that was not visible in the image/video clips provided.

Thank you for this referral. If the clinical or image interpretation does not parallel your findings or if I can be of any further assistance please contact me.

BREED

DLH

Sebastian Schaub, Sebastian Schaub, DVM, Dr. med. vet. DipECVDI
sebast.schaub@gmail.com

SEX

MN

AGE

15 Years

INTERPRETED BY

Sebastian Schaub, DVM
Dr. med. vet. DipECVDI

HOSPITAL NAME

State Avenue Vet
Clinic

REFERRING VET

Dr. Jessie Evoniuk

INVOICE

54490

DATE

10-6-22