**PATIENT PRESENTING CLINICAL SIGNS**

Rocco Allum History: Pitting edema in right hind limb from hock distally since June 2021. Responsive to prednisone. Right popliteal slightly enlarged.

SPECIES Abnormal PE/Chem/CBC/UA Results: Slight increase WBC $15.8 \times 10^9/L$

Canine **COMPUTED TOMOGRAPHIC STUDY OF THE HIND LIMBS**

A high resolution pre- and post-contrast CT study of the hind limbs is provided for review.

BREED**COMPUTED TOMOGRAPHIC FINDINGS**

Shepherd X

The outer margins of the soft tissues of the most distal aspects of both hind limbs are overexposed and 'burned-out'.

SEX

Intact Male

The popliteal lymph nodes bilaterally are within normal limits.

The osseous structures of the hind limbs are within normal limits.

AGE

1 Year

COMPUTED TOMOGRAPHIC DIAGNOSIS

- Lymphadenopathy popliteal lymph nodes

INTERPRETED BY

Sebastian Schaub,
DVM Dr. med. vet.
DipECVDI

INTERPRETATION OF THE FINDINGS & FURTHER RECOMMENDATIONS

Unfortunately, more thorough evaluation of the surrounding soft tissues of the distal aspects of the hind limbs is limited by the overexposure, but no overt abnormalities can be appreciated. Potentials include vasculitis, AV-malformation, infection, neoplasia, genetic predisposition for lymphedema. If not done so yet, FNA sampling of the enlarged lymph nodes is recommended to check for potential primary inflammatory origin. Biopsy of the affected tissue might be a consideration as well.

HOSPITAL NAME

Bridgwater VH & WC

REFERRING VET

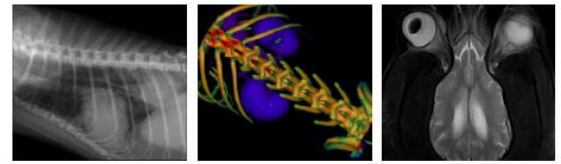
Dr. D. Faucher

INVOICE

13582

DATE

10/6/21



PATIENT

Rocco Allum

SPECIES

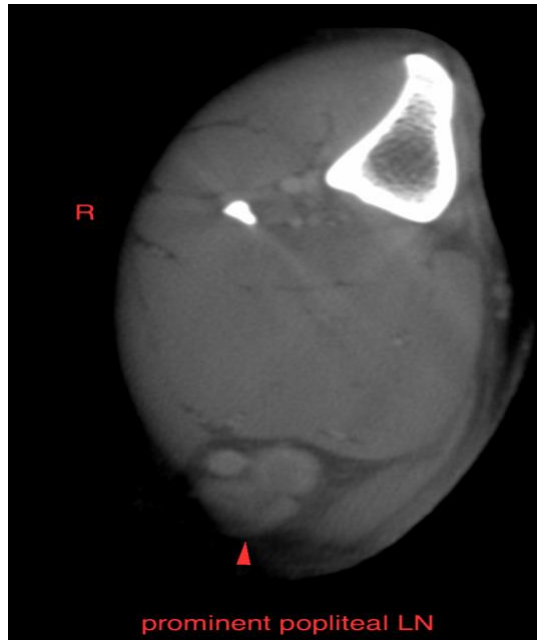
Canine

BREED

Shepherd X

SEX

Intact Male



AGE

1 Year

The information and recommendations provided are based on the images presented by the referring veterinarian. No evaluation can be communicated regarding pathology that was not visible in the image/video clips provided.

INTERPRETED BY

Sebastian Schaub,
DVM Dr. med. vet.
DipECVDI

Thank you for this referral. If the clinical or image interpretation does not parallel your findings or if I can be of any further assistance please contact me.

Sebastian Schaub, Sebastian Schaub, DVM, Dr. med. vet. DipECVDI
sebast.schaub@gmail.com

HOSPITAL NAME

Bridgwater VH & WC

REFERRING VET

Dr. D. Faucher

INVOICE

13582

DATE

10/6/21