



**PATIENT PRESENTING CLINICAL SIGNS**

Levi Rusconi Seizure activity, ruling out epilepsy vs CNS lesion

**COMPUTED TOMOGRAPHY OF THE SKULL**

**SPECIES** A high resolution pre- and post-contrast CT study of the skull is provided for review.

K9 **COMPUTED TOMOGRAPHIC FINDINGS**

The pictured parts of the dentition are complete and unremarkable in all jaw quadrants.

**BREED** The nasal cavity presents the expected aerated spaces between thin & even conchae and turbinates with smooth mucosal lining.

Husky Mix Both temporomandibular joints present congruent joint spaces with even subchondral bone surfaces and are considered within normal limits.

**SEX** Both tympanic bullae are aerated, the mucosal lining is not seen, the bony wall is smooth and thin. The external ear canals are within normal limits.

MN The brain presents no deviation from normal anatomy and symmetry. The brain parenchyma is homogeneous and within normal limits for attenuation and distribution of contrast enhancement. The ventricular system is non-dilated and symmetric.

**AGE** 1 Year The submandibular and medial retropharyngeal lymph nodes are small and elongated with a normal short-to-long-axis-ratio is < 0.5, the attenuation and contrast enhancement pattern is uniform.

**INTERPRETED BY**

Sebastian Schaub, DVM  
Dr. med. vet. DipECVDI

**COMPUTED TOMOGRAPHIC DIAGNOSIS**

- Normal brain

**HOSPITAL NAME**

Rockaway Animal Hospital

**INTERPRETATION OF THE FINDINGS & FURTHER RECOMMENDATIONS**

In the present study of the brain there is no evidence of macromorphological disease, which supports the presumptive diagnosis of idiopathic epilepsy.

If not yet done so the workup should be complemented by examination of CSF and complete bloodwork to screen for brain disease that is not necessarily associated with structural changes of the brain parenchyma and rule out hepatoencephalopathy and other systemic illness. In case of the strong clinical suspicion of structural intraparenchymal changes an MRI may be considered.

**REFERRING VET**

Dr. Maniar

**INVOICE**

54474

**DATE**

10-5-22



**PATIENT**

Levi Rusconi

**SPECIES**

K9

**BREED**

Husky Mix

**SEX**

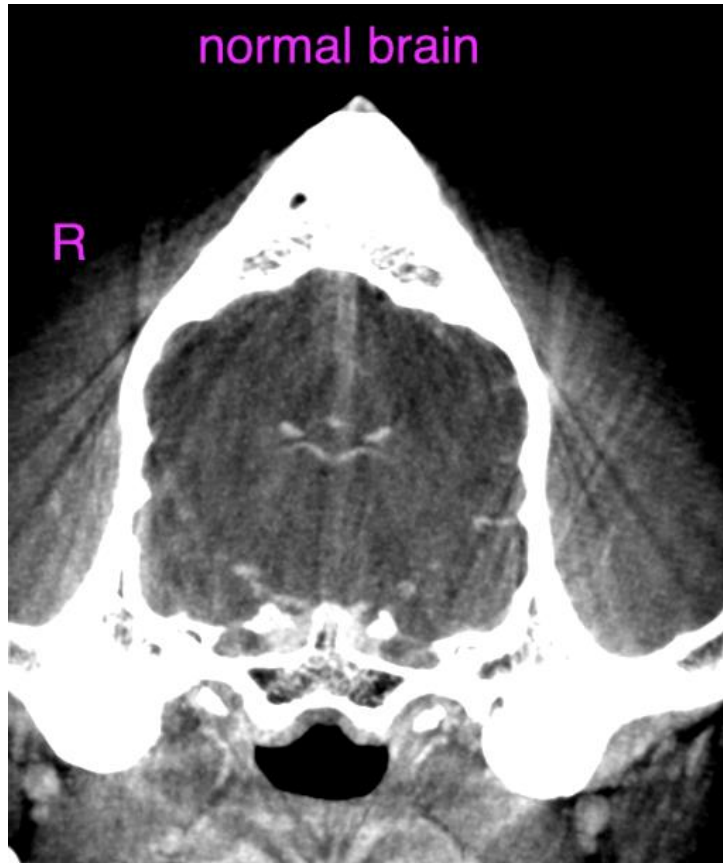
MN

**AGE**

1 Year

**INTERPRETED BY**

Sebastian Schaub, DVM  
Dr. med. vet. DipECVDI



**HOSPITAL NAME**

Rockaway Animal  
Hospital

**REFERRING VET**

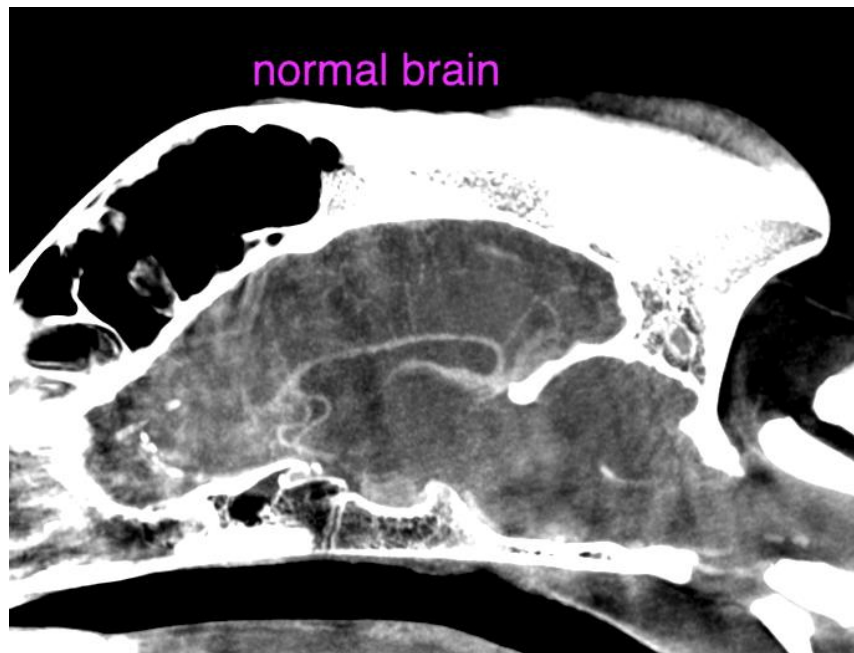
Dr. Maniar

**INVOICE**

54474

**DATE**

10-5-22





**PATIENT**

Levi Rusconi

**SPECIES**

K9

The information and recommendations provided are based on the images presented by the referring veterinarian/sonographer. No evaluation can be communicated regarding pathology that was not visible in the image/video clips provided.

**BREED**

Husky Mix

Thank you for this referral. If the clinical or image interpretation does not parallel your findings or if I can be of any further assistance please contact me.

**Sebastian Schaub**, Sebastian Schaub, DVM, Dr. med. vet. DipECVDI  
sebast.schaub@gmail.com

**SEX**

MN

**AGE**

1 Year

**INTERPRETED BY**

Sebastian Schaub, DVM  
Dr. med. vet. DipECVDI

**HOSPITAL NAME**

Rockaway Animal  
Hospital

**REFERRING VET**

Dr. Maniar

**INVOICE**

54474

**DATE**

10-5-22