



PATIENT PRESENTING CLINICAL SIGNS

Dipper Dafydd History: Pt presents for COHAT w Full Mouth extractions.
Abnormal PE/Chem/CBC/UA Results:

SPECIES COMPUTED TOMOGRAPHIC STUDY OF THE SKULL

Canine A high resolution plain CT study of the skull is are provided for review.

COMPUTED TOMOGRAPHIC FINDINGS

BREED

Miniature Pinscher

The tooth elements 110, 311, 401-403, 410 and 411 are absent. A moderate to marked amount of mineral attenuating material is attached to the crowns of the premolar and molar teeth. All premolar and molar teeth present a moderate to marked widening of the periodontal space with furcation due to significant horizontal bone loss in all jaw quadrants. The palatine mesial root of triadan 108 is perforating the nasal cavity.

SEX

Neutered Male

The nasal cavity presents the expected aerated spaces between thin and even conchae and turbinates with smooth mucosal lining.

AGE

8 Years 7 Months

Both temporomandibular joints present congruent joint spaces with even subchondral bone surfaces and are considered within normal limits.

Both tympanic bullae are aerated, the mucosal lining is not seen, the bony wall is smooth and thin. The external ear canals are within normal limits.

INTERPRETED BY

Sebastian Schaub,
DVM Dr. med. vet.
DipECVDI

The brain presents no deviation from normal anatomy and symmetry.

The submandibular and medial retropharyngeal lymph nodes are prominent.

HOSPITAL NAME

South Bay AH & PR

COMPUTED TOMOGRAPHIC DIAGNOSIS

- Generalized moderate to marked periodontal disease
- Oronasal fistula formation 108
- Multiple absent teeth, see above
- Dental tartar
- Lymphadenopathy tributary lymph nodes of the skull

REFERRING VET

Ravinder Atwal

INTERPRETATION OF THE FINDINGS & FURTHER RECOMMENDATIONS

INVOICE

13577

The findings are consistent with generalized advanced periodontal disease, most accentuated in the upper jaw quadrants. Full mouth extraction has already been performed, regarding the history.

DATE

10/5/21



PATIENT

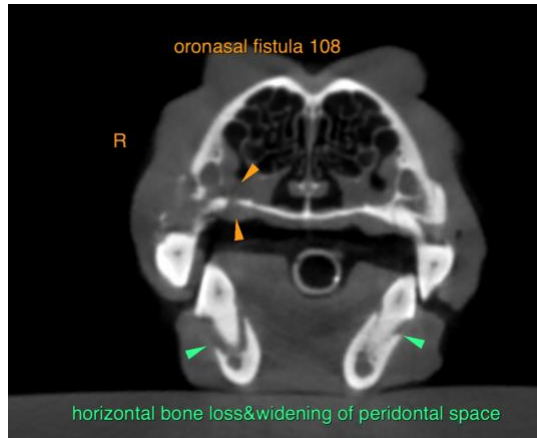
Dipper Dafydd

SPECIES

Canine

BREED

Miniature Pinscher



SEX

Neutered Male

AGE

8 Years 7 Months

The information and recommendations provided are based on the images presented by the referring veterinarian. No evaluation can be communicated regarding pathology that was not visible in the image/video clips provided.

Thank you for this referral. If the clinical or image interpretation does not parallel your findings or if I can be of any further assistance please contact me.

Sebastian Schaub, Sebastian Schaub, DVM, Dr. med. vet. DipECVDI
sebast.schaub@gmail.com

INTERPRETED BY

Sebastian Schaub,
DVM Dr. med. vet.
DipECVDI

HOSPITAL NAME

South Bay AH & PR

REFERRING VET

Ravinder Atwal

INVOICE

13577

DATE

10/5/21