



PATIENT

Kevin Durrant (K.D.)
Laracuenta

PRESENTING CLINICAL SIGNS

Follow-up xrays after fasting overnight. BW: wnl, cpl still pending.

SPECIES

Canine

RADIOGRAPHIC STUDY OF THE ABDOMEN

Radiographs of the abdomen in three imaging planes are provided for review.

BREED

Yorkshire Terrier

RADIOGRAPHIC FINDINGS

The surrounding bony structures are within normal limits.

SEX

Male

No abnormalities of the extraabdominal soft tissues are noted. The abdominal wall is smooth and thin.

AGE

11 Years

The serosal detail is maintained throughout the peritoneal and retroperitoneal space.

The liver is appropriate in position, size and presents uniform opacity.

The splenic head is in the anticipated position and within normal limits for size and opacity. The splenic body and tail are considered normal for position, size, shape and opacity.

Both kidneys are seen and present with normal size, shape, delineation and opacity. The urinary bladder is in its anticipated position. No radiopaque calculi are noted throughout the upper and lower urinary tract.

The stomach is in its anticipated position and is empty. The gastric wall is subjectively mildly prominent

INTERPRETED BY

Sebastian Schaub, DVM
Dr. med. vet. DipECVDI

The small intestinal loops are of even diameter and non-dilated, a small amount of gas is seen within the small intestinal loops and considered within normal limits.

The colon is seen in the expected position and presents with appropriate content.

HOSPITAL NAME

The Pet Hospital of
Stratford

RADIOGRAPHIC DIAGNOSIS

- Possible mild thickening of the gastric wall

REFERRING VET

Dr. Claudia Giuliani

INTERPRETATION OF THE FINDINGS & FURTHER RECOMMENDATIONS

The subjective mild thickening of the gastric wall can indicate gastritis or less likely diffuse neoplastic infiltration of the gastric wall. Be aware that evaluation of the gastric wall is very limited by radiography and if clinical signs persist under empirical management, ultrasound can be used to rule in/out mural changes of the gastric wall entirely.

INVOICE

54418

DATE

10-4-22



PATIENT

Kevin Durrant (K.D.)
Laracuenta

SPECIES

Canine

BREED

Yorkshire Terrier

SEX

Male

AGE

11 Years

INTERPRETED BY

Sebastian Schaub, DVM
Dr. med. vet. DipECVDI

HOSPITAL NAME

The Pet Hospital of
Stratford

REFERRING VET

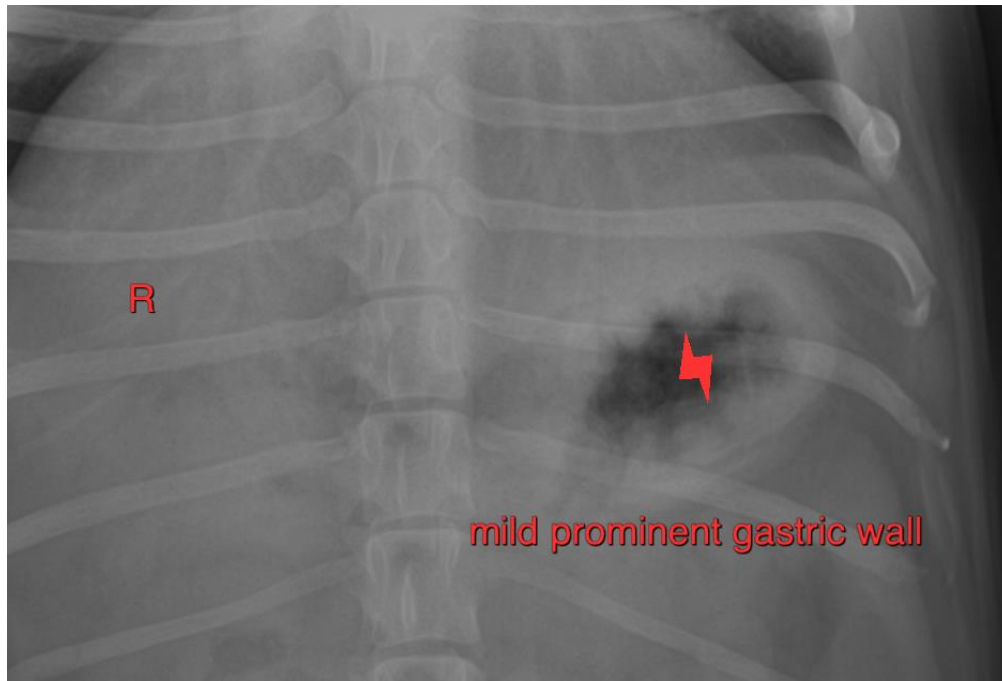
Dr. Claudia Giuliani

INVOICE

54418

DATE

10-4-22



The information and recommendations provided are based on the images presented by the referring veterinarian/sonographer. No evaluation can be communicated regarding pathology that was not visible in the image/video clips provided.

Thank you for this referral. If the clinical or image interpretation does not parallel your findings or if I can be of any further assistance please contact me.

Sebastian Schaub, Sebastian Schaub, DVM, Dr. med. vet. DipECVDI
sebast.schaub@gmail.com