



PATIENT

Alvin Keller

PRESENTING CLINICAL SIGNS

Requested By: Dr.Raul Casas Supplier: In House Diagnostics Reference: US1745-DR138 Focused Ultrasound Outcome: Hypoechoic center with hyperechoic surroundings; it seemed like an abscess; there might be some communication with some of the neck vessels; attempted aspiration with a 20ga, 18ga and 16ga needles; only obtained blood clots

SPECIES

Canine

COMPUTED TOMOGRAPHY OF THE CRANIAL NECK

A high resolution pre- and post-contrast CT study of the neck is provided for review.

BREED

Mixed

COMPUTED TOMOGRAPHIC FINDINGS

A generalized moderate swelling of the left retropharyngeal tissue with significant fat-stranding of the retropharyngeal and submandibular fat is appreciated.

SEX

Male Neutered

The left medial retropharyngeal lymph node and the left mandibular lymph nodes are moderately enlarged and rounded with a uniform contrast enhancement pattern.

COMPUTED TOMOGRAPHIC DIAGNOSIS

- Lymphadenopathy left medial retropharyngeal and left mandibular lymph nodes
- Steatitis left retropharyngeal & submandibular region

AGE

6 Years

INTERPRETATION OF THE FINDINGS & FURTHER RECOMMENDATIONS

An underlying cause for the enlarged left medial retropharyngeal and mandibular lymph nodes with accompanying steatitis is not appreciated. Septic lymphadenitis versus sterile granulomatous lymphadenopathy need to be considered. Neoplastic infiltration (e.g. mast cell tumor) is a consideration as well. There is no evidence of vascular invasion.

At this point I do not see evidence of a cavitary lesion.

INTERPRETED BY

Sebastian Schaub, DVM
Dr. med. vet. DipECVDI

HOSPITAL NAME

State Avenue Vet
Clinic

REFERRING VET

Dr. Raul Casas-Dolz

INVOICE

54441

DATE

10-4-22



PATIENT

Alvin Keller

SPECIES

Canine

BREED

Mixed

SEX

Male Neutered

AGE

6 Years

INTERPRETED BY

Sebastian Schaub, DVM
Dr. med. vet. DipECVDI

HOSPITAL NAME

State Avenue Vet
Clinic

REFERRING VET

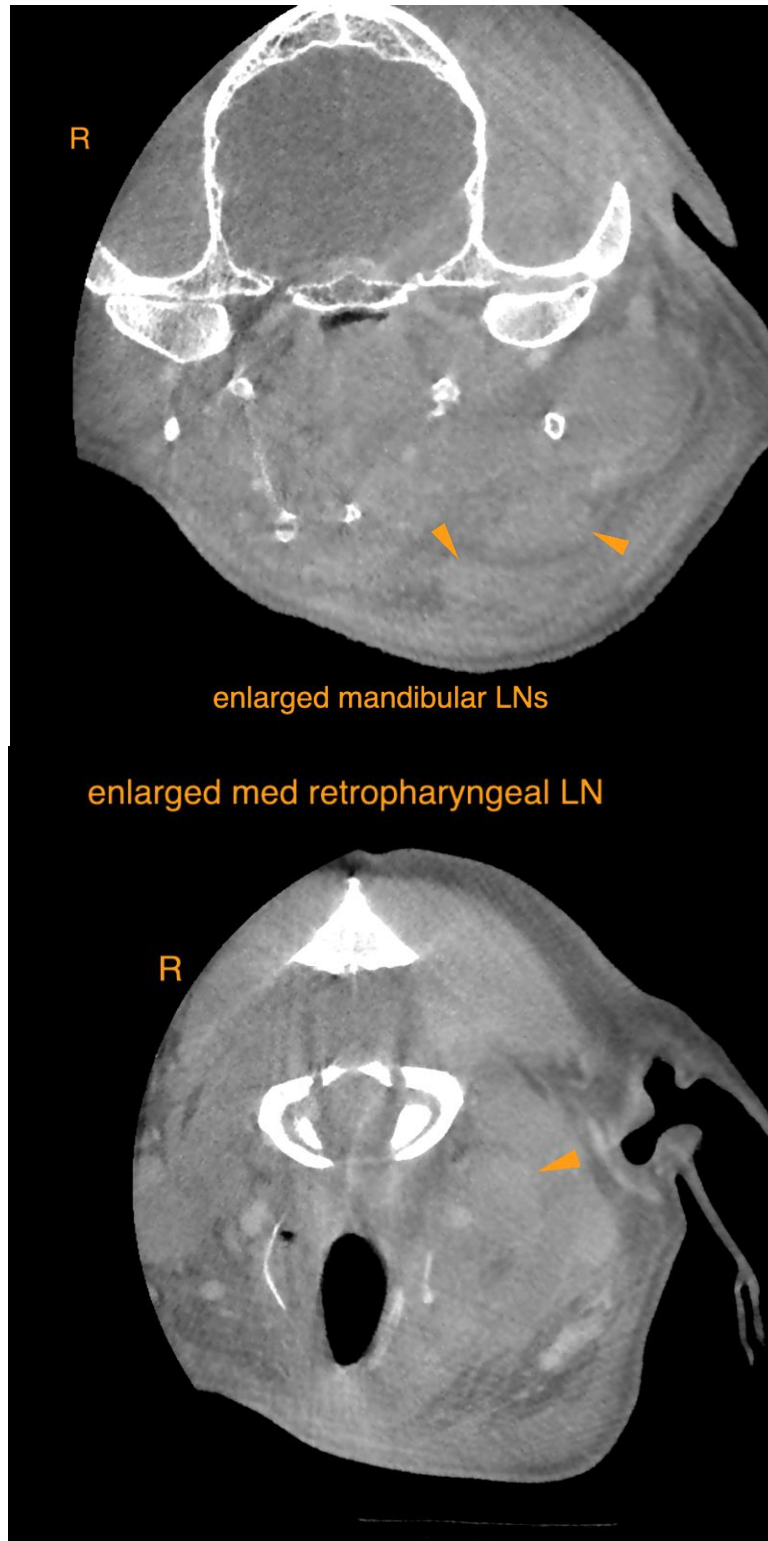
Dr. Raul Casas-Dolz

INVOICE

54441

DATE

10-4-22





PATIENT

Alvin Keller

The information and recommendations provided are based on the images presented by the referring veterinarian/sonographer. No evaluation can be communicated regarding pathology that was not visible in the image/video clips provided.

SPECIES

Canine

Thank you for this referral. If the clinical or image interpretation does not parallel your findings or if I can be of any further assistance please contact me.

BREED

Mixed

Sebastian Schaub, Sebastian Schaub, DVM, Dr. med. vet. DipECVDI
sebast.schaub@gmail.com

SEX

Male Neutered

AGE

6 Years

INTERPRETED BY

Sebastian Schaub, DVM
Dr. med. vet. DipECVDI

HOSPITAL NAME

State Avenue Vet
Clinic

REFERRING VET

Dr. Raul Casas-Dolz

INVOICE

54441

DATE

10-4-22