



PATIENT PRESENTING CLINICAL SIGNS

Reilly Thumann History: Reilly presented for reoccurring ear infection for the past 6-8 weeks.As per RDVM there is a small mass growing within right ear canal.
Abnormal PE/Chem/CBC/UA Results:

SPECIES COMPUTED TOMOGRAPHIC STUDY OF THE SKULL

Canine A high resolution post-contrast CT study of the skull is provided for review.

BREED COMPUTED TOMOGRAPHIC FINDINGS

Cocker Spaniel Triadan 305 & 405 are absent.

SEX The nasal cavity presents the expected aerated spaces between thin and even conchae and turbinates with smooth mucosal lining.

Spayed Female Both temporomandibular joints present congruent joint spaces with even subchondral bone surfaces and are considered within normal limits.

AGE Both tympanic bullae are aerated, the mucosal lining is not seen, the bony wall is smooth and thin. 15 Years 10 Months The right external ear canal contains heterogeneous contrast enhancing material and is moderately to markedly distended by the intraluminal mass. There is evidence of perforation of the ventral wall of the horizontal segment of the right external ear canal with the contrast enhancing material extending into the soft tissues ventrally. The surrounding fat presents mild to moderate fat stranding.

INTERPRETED BY Sebastian Schaub, DVM Dr. med. vet. DipECVDI The brain presents no deviation from normal anatomy and symmetry. The brain parenchyma is homogeneous and within normal limits for attenuation and distribution of contrast enhancement. The ventricular system is non-dilated and symmetric.

HOSPITAL NAME The right parotid and medial retropharyngeal lymph node are moderately enlarged, rounded and heterogeneous contrast enhancing.

Animal Surgical Center **COMPUTED TOMOGRAPHIC DIAGNOSIS**

- Mural mass right external ear canal with perforation of the right external ear canal
- Secondary focal steatitis
- No evidence of perforation of the right tympanic bulla
- Lymphadenopathy right parotid and medial retropharyngeal lymph node
- Absent triadan 305 & 405

INVOICE INTERPRETATION OF THE FINDINGS & FURTHER RECOMMENDATIONS

13525 The findings are consistent with primary neoplasia originating from the right external canal with perforation of the right external ear canal. The top differentials include ceruminous gland adenocarcinoma, squamous cell carcinoma or melanoma. The enlarged regional lymph nodes are

DATE
10/4/21



PATIENT

Reilly Thumann

highly suggestive for metastatic spread. Complete surgical excision of the mass by right sided total ear canal ablation appears feasible. Recommend FNA sampling of the respective lymph nodes and three view thoracic radiographs for complete tumor staging.

SPECIES

Canine

BREED

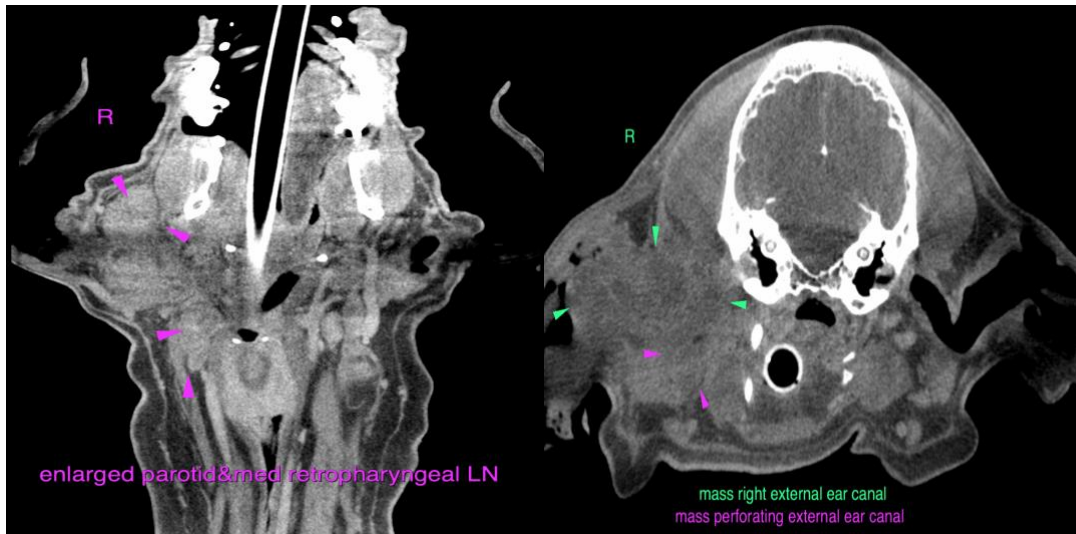
Cocker Spaniel

SEX

Spayed Female

AGE

15 Years 10 Months



The information and recommendations provided are based on the images presented by the referring veterinarian. No evaluation can be communicated regarding pathology that was not visible in the image/video clips provided.

INTERPRETED BY

Sebastian Schaub,
DVM Dr. med. vet.
DipECVDI

Thank you for this referral. If the clinical or image interpretation does not parallel your findings or if I can be of any further assistance please contact me.

Sebastian Schaub, Sebastian Schaub, DVM, Dr. med. vet. DipECVDI
sebast.schaub@gmail.com

HOSPITAL NAME

Animal Surgical
Center

REFERRING VET

Grady AH

INVOICE

13525

DATE

10/4/21