



PATIENT PRESENTING CLINICAL SIGNS

Lola Berkeley History: Left hind lameness of 1 month duration, worse after rest.

SPECIES

Canine

BREED

Pitbull

SEX

Spayed Female

AGE

11 Months

Abnormal PE/Chem/CBC/UA Results: Exam on 9/29: Patient toe-touching to weight-bearing lame left hind, worst after rising. Thickening of left stifle with effusion noted; unable to appreciate cranial drawer or tibial thrust. Patient started on 50mg carprofen Q12h. Patient returned for sedated orthopedic exam and radiographs on 10/4. Chemistry showed slightly elevated Phos 7.2(2.9-6.6) and decreased Glob 1.9(2.3-5.2). Orthopedic exam under sedation showed no appreciable stifle instability either side but effusion and hard thickening of joint still present in left stifle, no appreciable difference from 9/29. No crepitus appreciated in either stifle or hips.

RADIOGRAPHIC STUDY OF THE STIFLE JOINTS

A complete set of radiographs of the stifle joints is provided for review.

RADIOGRAPHIC FINDINGS

The left stifle joint presents with a marked intracapsular soft tissue swelling. The osseous margins of both stifle joints present smooth margins.

The right stifle joint presents a mild to moderate intracapsular swelling.

RADIOGRAPHIC DIAGNOSIS

- Articular swelling left stifle joint
- Possible articular swelling right stifle joint versus normal age related variant

INTERPRETATION OF THE FINDINGS & FURTHER RECOMMENDATIONS

The joint effusion of the left stifle joint in absence of any instability is concerning for arthritis and both immune mediated or infectious arthritis are considerations. Articular hemorrhage secondary to trauma might be a potential as well. There is no evidence of osseous abnormalities/fracture. If not done so yet, a synovial tap including sampling for microbial culture is mandatory for further workup.

If any form of arthritis can be ruled out, the marked distension of the joint capsule might stabilize the joint in case of pathology of the cruciate ligament.

INTERPRETED BY

Sebastian Schaub,
DVM Dr. med. vet.
DipECVCI

HOSPITAL NAME

Four Legs AH

REFERRING VET

Tenley Diaz

INVOICE

13519

DATE

10/4/21



PATIENT

Lola Berkeley

SPECIES

Canine

BREED

Pitbull

SEX

Spayed Female

AGE

11 Months

INTERPRETED BY

Sebastian Schaub,
DVM Dr. med. vet.
DipECVDI

HOSPITAL NAME

Four Legs AH

REFERRING VET

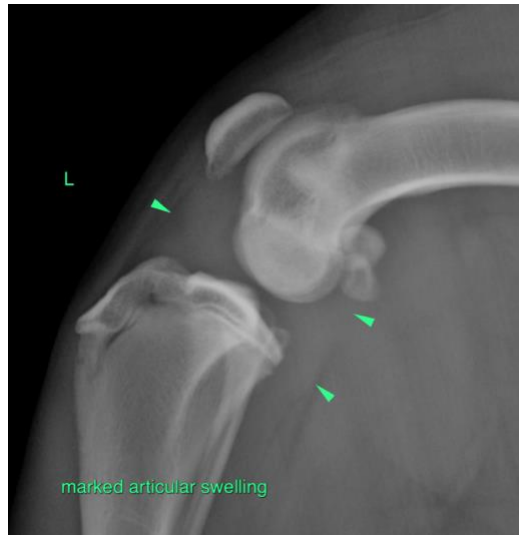
Tenley Diaz

INVOICE

13519

DATE

10/4/21



The information and recommendations provided are based on the images presented by the referring veterinarian. No evaluation can be communicated regarding pathology that was not visible in the image/video clips provided.

Thank you for this referral. If the clinical or image interpretation does not parallel your findings or if I can be of any further assistance please contact me.

Sebastian Schaub, Sebastian Schaub, DVM, Dr. med. vet. DipECVDI
sebast.schaub@gmail.com