



**PATIENT PRESENTING CLINICAL SIGNS**

Dixie Hunter History: Vomiting and diarrhea for the last 3 days. Did get into a carcass a few days ago. Abnormal PE/Chem/CBC/UA Results: PE normal. Labs pending.

**SPECIES RADIOGRAPHIC STUDY OF THE ABDOMEN**

Canine Radiographs of the abdomen in three imaging planes are provided for review.

**RADIOGRAPHIC FINDINGS**

**BREED**

Standard Poodle The vertebral endplates L2/L3 present moderate spondylosis formation.

No abnormalities of the extraabdominal soft tissues are noted. The abdominal wall is smooth and thin.

**SEX**

The serosal detail is mildly decreased due to the lean body condition.

Spayed Female

The liver is appropriate in position, size and presents uniform opacity.

**AGE**

The splenic head is in the anticipated position and within normal limits for size and opacity. The splenic body and tail are considered normal for position, size, shape and opacity.

4 Years

Both kidneys are seen and present with normal size, shape, delineation and opacity. The urinary bladder is in its anticipated position. No radiopaque calculi are noted throughout the upper and lower urinary tract.

**INTERPRETED BY**

Sebastian Schaub,  
DVM Dr. med. vet.  
DipECVDI

The stomach is in its anticipated position and presents normal content.

The small intestinal loops are of even diameter and contain generalized a mild amount of gas. The colon is seen in the expected position and presents with appropriate content.

**HOSPITAL NAME**

Pinebrook AH

**RADIOGRAPHIC DIAGNOSIS**

- Gas pattern of intestinal tract
- Spondylosis deformans L2/L3

**REFERRING VET**

Dr. Britt Dubil

**INTERPRETATION OF THE FINDINGS & FURTHER RECOMMENDATIONS**

The radiographic study is most consistent with gastroenteritis. There is no evidence of radiopaque foreign material or signs for gastrointestinal mechanical obstruction. Recommend empirical management. If clinical signs are refractory to therapy, follow up radiographs of the abdomen or an abdominal ultrasound examination are recommended.

**INVOICE**

13535

**DATE**

10/4/21



**PATIENT**

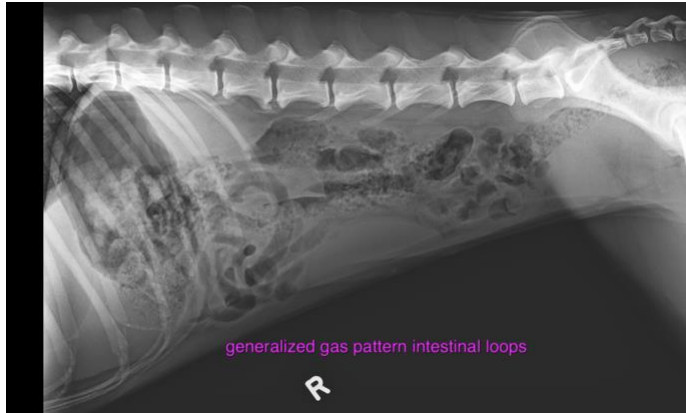
Dixie Hunter

**SPECIES**

Canine

**BREED**

Standard Poodle



**SEX**

Spayed Female

**AGE**

4 Years

**The information and recommendations provided are based on the images presented by the referring veterinarian. No evaluation can be communicated regarding pathology that was not visible in the image/video clips provided.**

Thank you for this referral. If the clinical or image interpretation does not parallel your findings or if I can be of any further assistance please contact me.

**Sebastian Schaub**, Sebastian Schaub, DVM, Dr. med. vet. DipECVDI  
sebast.schaub@gmail.com

**INTERPRETED BY**

Sebastian Schaub,  
DVM Dr. med. vet.  
DipECVDI

**HOSPITAL NAME**

Pinebrook AH

**REFERRING VET**

Dr. Britt Dubil

**INVOICE**

13535

**DATE**

10/4/21