



**PATIENT PRESENTING CLINICAL SIGNS**

**Bella Gigliotti** History: Bella is a twelve year old, FS, Pomeranian with a chronic history of abnormal gait. Recently, Bella was presented on 9/27/21 for dragging RH leg , RH leg giving out and refusal to jump on couch. Bella is chronically taking meloxidyl and gabapentin (BID gabapentin was recently decreased to SID and 2 days after decrease, Bella began limping). On exam, Bella showed discomfort on palpation at T10-T13, conscious proprioception was absent both hind legs, but deep pain was present. Thoracic and lumbar spine radiographs and neurology referral were advised.  
**Abnormal PE/Chem/CBC/UA Results:**

**BREED RADIOGRAPHIC STUDY OF THE THORAX AND ABDOMEN/LUMBAR SPINE**

**Pomeranian** An overview study including the thorax and abdomen/lumbar spine in two imaging planes is provided for review.

**SEX RADIOGRAPHIC FINDINGS**

**Spayed Female** The intervertebral disc spaces T12/T13 and T13/L1 are collapsed. The vertebral endplates T13/L1 show evidence of chronic osseous remodeling with spondylosis formation.

**AGE** The patella of the left stifle joint is superimposed on the medial femoral condyle.

**12 Years** Mineralized material is seen in the imaging plane of the right kidney.

**INTERPRETED BY RADIOGRAPHIC DIAGNOSIS**

- Sebastian Schaub, DVM Dr. med. vet. DipECVDI**
- Chronic discopathy T12/T13 and T13/L1
  - Chronic osseous remodeling vertebral endplates T13/L1
  - Left sided medial patellar luxation
  - Suspect right sided nephrolithiasis
  - Normal thorax

**HOSPITAL NAME**

Lambs Gap AH

**INTERPRETATION OF THE FINDINGS & FURTHER RECOMMENDATIONS**

**REFERRING VET**

Dr. Jennifer Todd

There is evidence of discopathy of the intervertebral discs T12/T13 and T13/L1 – the changes seen level T13/L1 are chronic with remodeling of the respective vertebral endplates. Based on the neurological clinical signs, cross-sectional imaging would be needed to detect clinically relevant myelocompression.

**INVOICE**

13497

**DATE**

10/4/21



**PATIENT**

Bella Gigliotti

**SPECIES**

Canine

**BREED**

Pomeranian

**SEX**

Spayed Female

**AGE**

12 Years

**INTERPRETED BY**

Sebastian Schaub,  
DVM Dr. med. vet.  
DipECVDI

**HOSPITAL NAME**

Lambs Gap AH

**REFERRING VET**

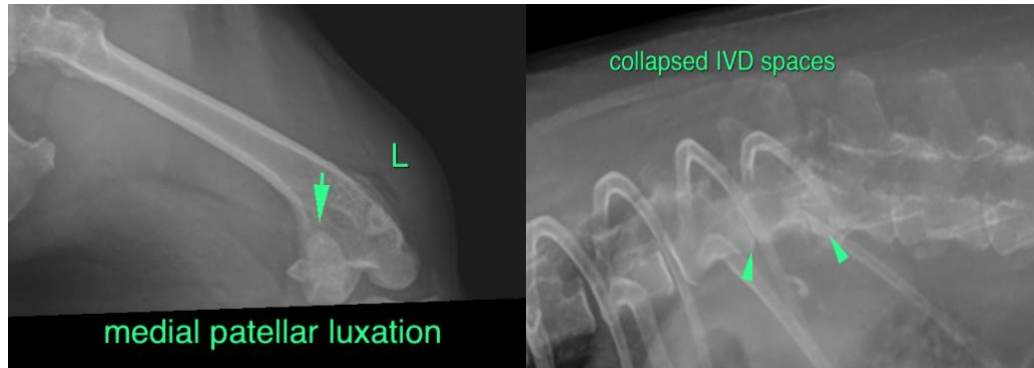
Dr. Jennifer Todd

**INVOICE**

13497

**DATE**

10/4/21



**The information and recommendations provided are based on the images presented by the referring veterinarian. No evaluation can be communicated regarding pathology that was not visible in the image/video clips provided.**

Thank you for this referral. If the clinical or image interpretation does not parallel your findings or if I can be of any further assistance please contact me.

**Sebastian Schaub**, Sebastian Schaub, DVM, Dr. med. vet. DipECVDI  
sebast.schaub@gmail.com