



PATIENT

Archie Nieves

SPECIES

Feline

BREED

DSH

SEX

Male

AGE

7 Years

WEIGHT

11 Pounds

INTERPRETED BY

Sebastian Schaub, DVM
Dr. med. vet. DipECVDI

IMAGING PERFORMED BY

HVSFA

HOSPITAL NAME

Hospital Veterinario
San Francisco de Asis

REFERRING VET

Dr. Vega

INVOICE

35382

DATE

10/31/25

PRESENTING CLINICAL SIGNS

History: Patient was referred for a CT scan due to intermittent lameness of the forelimb, with only mild improvement following NSAID therapy. Swelling and pain were noted upon palpation of the ventral musculature along the ulna. Additionally, the patient presents with unilateral nasal discharge from the left nostril (yellowish to sanguineous) and persistent sneezing despite treatment with cetirizine.

COMPUTED TOMOGRAPHIC STUDY OF THE SKULL & FRONT LIMBS

A high resolution pre- and post-contrast CT study of the skull and abdomen and a post-contrast CT study of the thorax is provided for review.

COMPUTED TOMOGRAPHIC Findings

Skull

The pictured parts of the dentition are complete and unremarkable in all jaw quadrants.

In both nasal cavities, a small amount of fluid attenuating material is attached to the nasal mucosal lining. Mild destruction of the left nasal conchal structures is appreciated.

Both temporomandibular joints present congruent joint spaces with even subchondral bone surfaces and are considered within normal limits.

Both tympanic bullae are aerated, the mucosal lining is not seen, the bony wall is smooth and thin. The external ear canals are within normal limits.

The brain presents no deviation from normal anatomy and symmetry. The brain parenchyma is homogeneous and within normal limits for attenuation and distribution of contrast enhancement. The ventricular system is non-dilated and symmetric.

The submandibular and medial retropharyngeal lymph nodes are small and elongated with a normal short-to-long-axis-ratio is < 0.5, the attenuation and contrast enhancement pattern is uniform.

Front Limbs

Both shoulder joints present smooth margins of the periarticular bones and the surrounding soft tissue structures are within normal limits.

Accentuated the medial aspect of the right humeral condyle presents a diffuse sclerosis, surrounding a hypoattenuating zone within the subchondral bone of the trochlea humeri – presenting a shallow concave depression of the joint surface.

At the caudodistal aspect of the medial humeral epicondyle bilaterally, a small (<1 mm), isolated mineralized body is seen. The remainder of the elbow joints present smooth margins of the periarticular bones

COMPUTED TOMOGRAPHIC DIAGNOSIS

- Osteochondrosis dissecans (OCD) right trochlea humeri
- Mild destructive rhinitis
- Small isolated ossification center caudodistal aspect medial humeral epicondyle bilaterally



PATIENT

- Normal shoulder joints

Archie Nieves

SPECIES

Feline

BREED

DSH

SEX

Male

AGE

7 Years

WEIGHT

11 Pounds

INTERPRETED BY

Sebastian Schaub, DVM
Dr. med. vet. DipECVDI

IMAGING PERFORMED BY

HVSFA

HOSPITAL NAME

Hospital Veterinario
San Francisco de Asis

REFERRING VET

Dr. Vega

INVOICE

35382

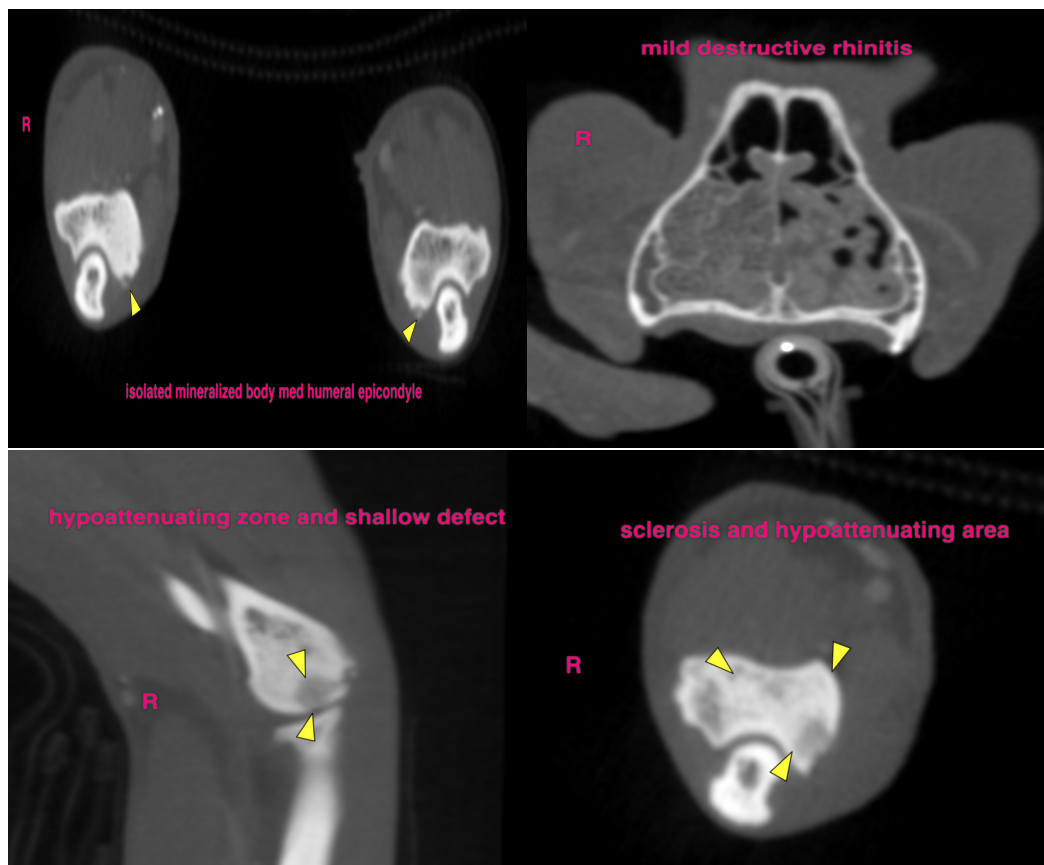
DATE

10/31/25

INTERPRETATION OF THE FINDINGS & FURTHER RECOMMENDATIONS

The OCD lesion of the right trochlea humeri is a plausible explanation for the intermittent right front limb lameness – possible surgical management options can be discussed with orthopedic surgeon.

The destructive rhinitis in feline patients is commonly primary viral ± bacterial or less likely mycotic superinfection. Rhinoscopy including sampling for histopathology and microbial culture can be used for specification - in many cases the initial causative infectious agent cannot be isolated anymore. In chronic cases of rhinosinusitis, clinical signs are prone to reoccur.



The information and recommendations provided are based on the images presented by the referring veterinarian/sonographer. No evaluation can be communicated regarding pathology that was not visible in the image/video clips provided.

Thank you for this referral. If the clinical or image interpretation does not parallel your findings or if I can be of any further assistance please contact me.

Sebastian Schaub, DVM, Dr. med. vet. DipECVDI
info@sonopath.com