



PATIENT

Spike Hudman

PRESENTING CLINICAL SIGNS

Right sided epistaxis noted several days ago; 2-3 nose bleeds since first noted. Positive for Valley Fever and currently undergoing Fluconazole treatment.

SPECIES

Canine

COMPUTED TOMOGRAPHY OF THE SKULL

A high resolution pre- and post-contrast CT study of the viscerocranium is provided for review.

BREED

Shepherd Mix

COMPUTED TOMOGRAPHIC FINDINGS

Triadan 106, 108, 205, 206, 208, 306, 308 and 408 present with ankylosis and resorptive lesions of the roots. Triadan 310 and 401 present a moderate widening of the periodontal space. Generalized mild horizontal bone loss is seen in all jaw quadrants.

SEX

MN

The nasal cavity presents the expected aerated spaces between thin & even conchae and turbinates with smooth mucosal lining. In the most rostral aspect of the right maxillary recess, a small amount of soft tissue attenuating material is appreciated.

AGE

14 Years

COMPUTED TOMOGRAPHIC DIAGNOSIS

- Ankylosis and tooth root resorption 106, 108, 205, 206, 208, 306, 308 and 408
- Advanced periodontal disease 310 and 401
- Generalized horizontal bone loss in all jaw quadrants due to generalized periodontal disease
- Normal nasal cavity but small amount of soft tissue material in rostral aspect right maxillary recess

INTERPRETED BY

Sebastian Schaub, DVM
Dr. med. vet. DipECVDI

INTERPRETATION OF THE FINDINGS & FURTHER RECOMMENDATIONS

There is no evidence for neoplastic disease of the nasal cavity, foreign body related rhinitis or oronasal fistula formation. The soft tissue material in the right maxillary recess is suggestive for small intranasal blood clot. Possible causes for epistaxis include immune mediated disease, non-specific rhinitis (e.g. lymphocytic plasmocytic), hyperviscosity syndrome (e.g. Leishmaniosis), other causes for coagulopathy or systemic hypertension.

HOSPITAL NAME

Scottsdale Veterinary
Clinic

REFERRING VET

Dr. Hertz

INVOICE

54895

DATE

10-31-22



PATIENT

Spike Hudman

SPECIES

Canine

BREED

Shepherd Mix

SEX

MN

AGE

14 Years

INTERPRETED BY

Sebastian Schaub, DVM
Dr. med. vet. DipECVDI

HOSPITAL NAME

Scottsdale Veterinary
Clinic

REFERRING VET

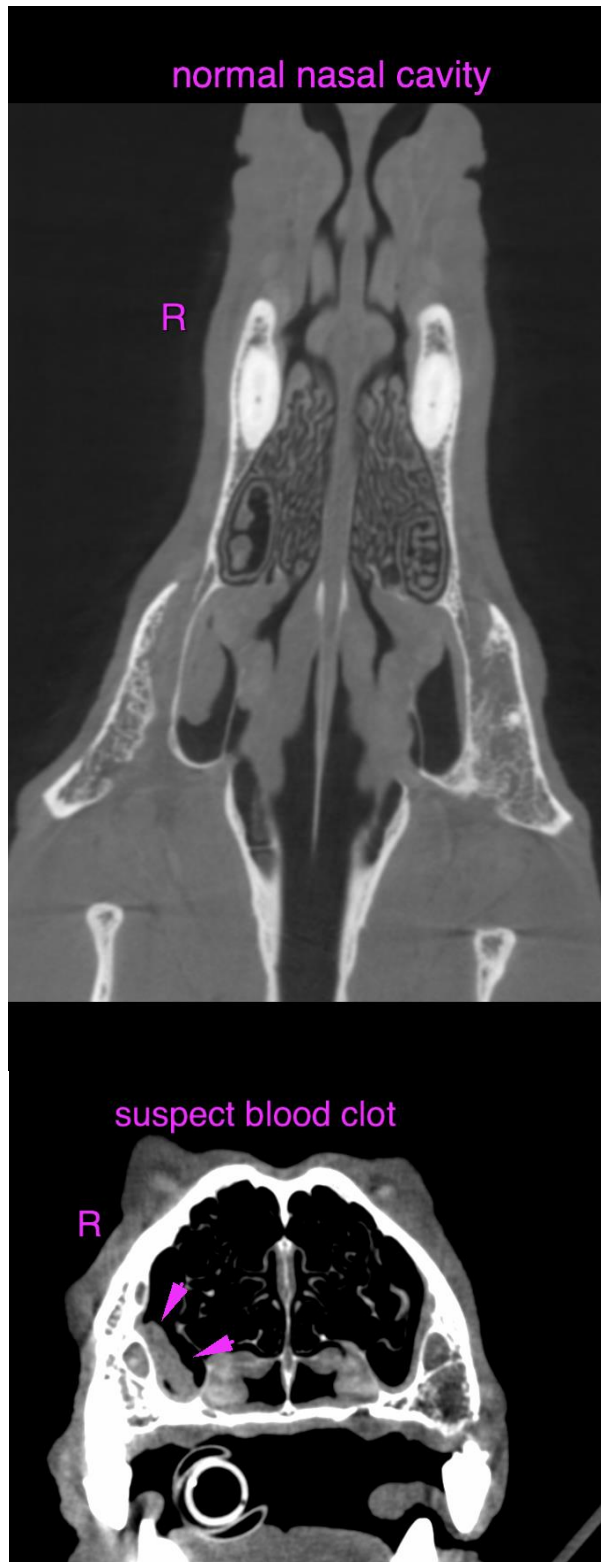
Dr. Hertz

INVOICE

54895

DATE

10-31-22





PATIENT

Spike Hudman

SPECIES

Canine

The information and recommendations provided are based on the images presented by the referring veterinarian/sonographer. No evaluation can be communicated regarding pathology that was not visible in the image/video clips provided.

BREED

Shepherd Mix

Thank you for this referral. If the clinical or image interpretation does not parallel your findings or if I can be of any further assistance please contact me.

Sebastian Schaub, Sebastian Schaub, DVM, Dr. med. vet. DipECVDI
sebast.schaub@gmail.com

SEX

MN

AGE

14 Years

INTERPRETED BY

Sebastian Schaub, DVM
Dr. med. vet. DipECVDI

HOSPITAL NAME

Scottsdale Veterinary
Clinic

REFERRING VET

Dr. Hertz

INVOICE

54895

DATE

10-31-22