



PATIENT PRESENTING CLINICAL SIGNS

Minnie Lantz presented for chronic bilateral purulent nasal discharge which has recently gotten worse. Also has a history of chronic intermittent vomiting.
Abnormal PE/Chem/CBC/UA Results: normal

SPECIES COMPUTED TOMOGRAPHY OF THE SKULL & THORAX

Feline A high resolution pre- and post-contrast CT study of the skull and a post-contrast CT study of the thorax are provided for review.

BREED COMPUTED TOMOGRAPHIC FINDINGS

DSH Skull

Triadan 207 is absent.

SEX Advanced destruction of the nasal conchal & turbinate structures is noted, resulting in an empty nose. The nasal mucosal lining is moderately thickened.

FS Both temporomandibular joints present congruent joint spaces with even subchondral bone surfaces and are considered within normal limits.

AGE Both tympanic bullae are aerated, the mucosal lining is not seen, the bony wall is smooth and thin. The external ear canals are within normal limits.

12 Years

INTERPRETED BY The brain presents no deviation from normal anatomy and symmetry. The brain parenchyma is homogeneous and within normal limits for attenuation and distribution of contrast enhancement. The ventricular system is non-dilated and symmetric.

Sebastian Schaub, DVM
Dr. med. vet. DipECVDI

The submandibular and medial retropharyngeal lymph nodes are small and elongated with a normal short-to-long-axis-ratio is < 0.5, the attenuation and contrast enhancement pattern is uniform.

HOSPITAL NAME Thorax

The bony and surrounding soft tissue structures are within normal limits.

Northeast Veterinary Referral Hospital

The sternal, cranial mediastinal and tracheobronchial lymph nodes are small elongated with a normal short-to-long-axis-ratio is < 0.5, the attenuation and contrast enhancement pattern is uniform and considered within normal limits.

REFERRING VET

Dr. Runde The cardiovascular structures including the pulmonary vasculature are within normal limits.

Generalized mild thickening of the bronchial walls is noted. In the craniodorsal aspect of the cranial part of the left cranial lung lobe, a subpleural small consolidated region is seen. The remainder of the lung parenchyma presents the expected architecture and attenuation behavior.

INVOICE

54878 Small incidental gas pockets are seen within the esophageal lumen, there is no evidence of abnormal dilation.

DATE COMPUTED TOMOGRAPHIC DIAGNOSIS

- 10-31-22
- Advanced destructive rhinitis
 - Bronchial lung pattern
 - Absent triadan 207



PATIENT

Minnie Lantz

INTERPRETATION OF THE FINDINGS & FURTHER RECOMMENDATIONS

The findings are consistent with advanced destructive rhinitis and both primary viral rhinitis with bacterial superinfection or mycotic rhinitis (e.g. Aspergillosis, Cryptococcosis) need to be considered.

SPECIES

Feline

Bilateral reactive lymphadenopathy of the submandibular lymph nodes.

Recommended rhinoscopy for further evaluation with sampling for culture and histopathology (detection of fungi microscopically is more straightforward than with culture in many cases).

BREED

DSH

The bronchial lung pattern indicates accompanying inflammatory lower airway disease.

SEX

FS

AGE

12 Years

INTERPRETED BY

Sebastian Schaub, DVM
Dr. med. vet. DipECVDI

HOSPITAL NAME

Northeast Veterinary
Referral Hospital

REFERRING VET

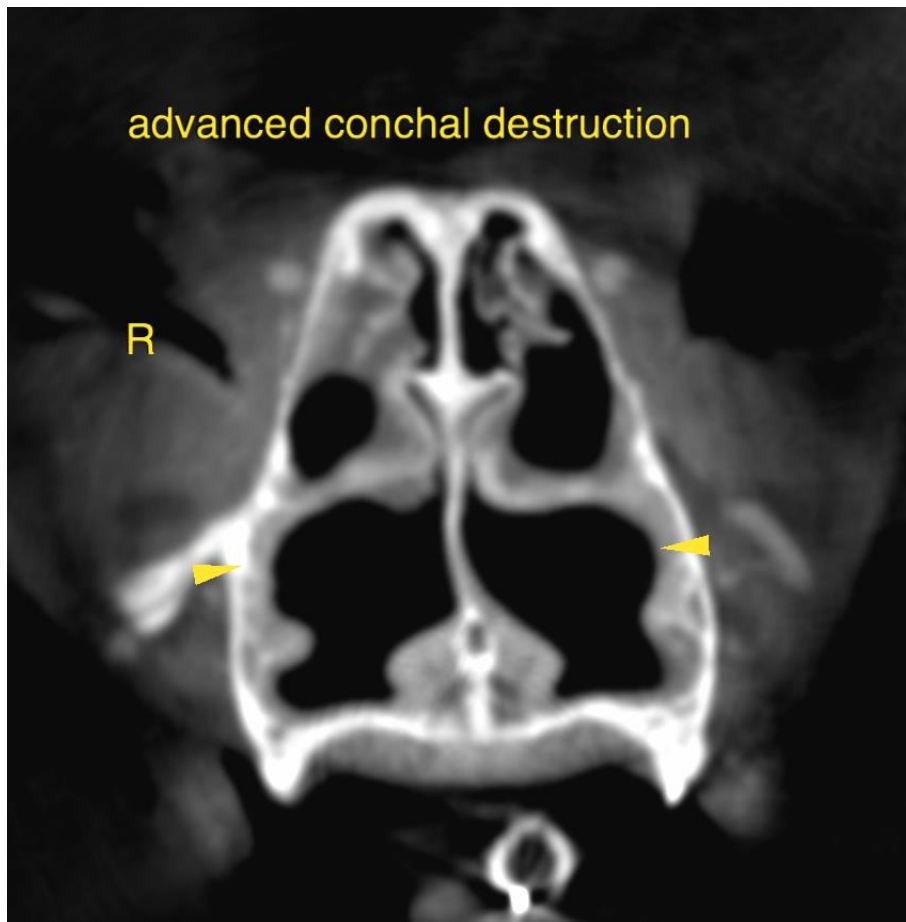
Dr. Runde

INVOICE

54878

DATE

10-31-22





PATIENT

Minnie Lantz

SPECIES

Feline

BREED

DSH

SEX

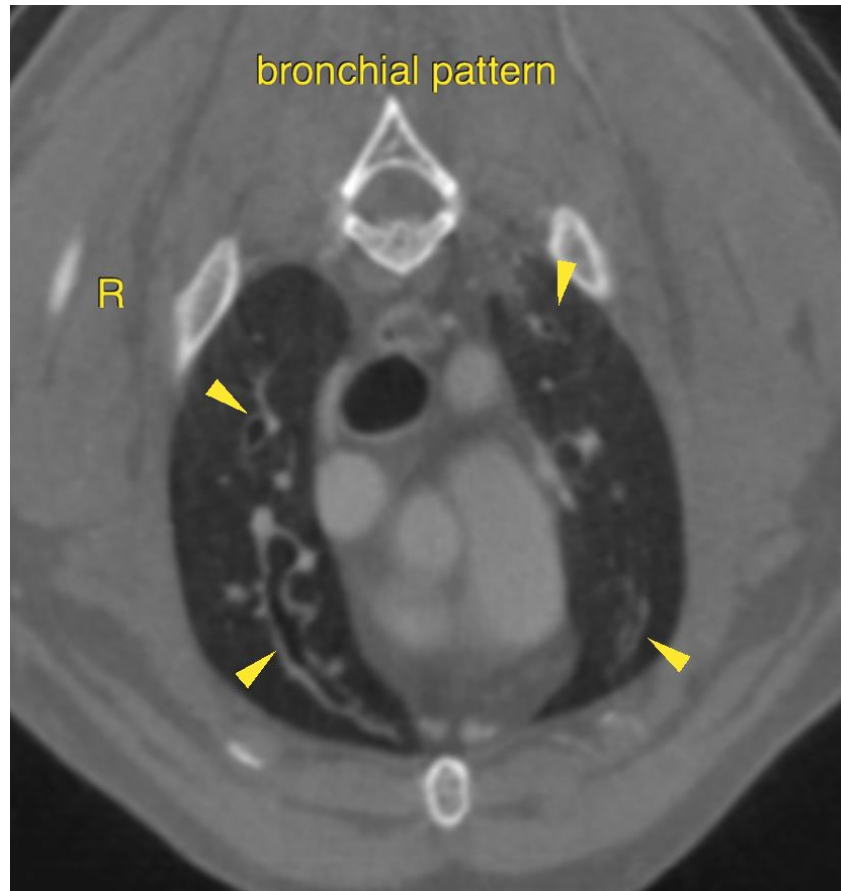
FS

AGE

12 Years

INTERPRETED BY

Sebastian Schaub, DVM
Dr. med. vet. DipECVDI



HOSPITAL NAME

Northeast Veterinary
Referral Hospital

REFERRING VET

Dr. Runde

INVOICE

54878

DATE

10-31-22

The information and recommendations provided are based on the images presented by the referring veterinarian/sonographer. No evaluation can be communicated regarding pathology that was not visible in the image/video clips provided.

Thank you for this referral. If the clinical or image interpretation does not parallel your findings or if I can be of any further assistance please contact me.

Sebastian Schaub, Sebastian Schaub, DVM, Dr. med. vet. DipECVDI
sebast.schaub@gmail.com