



PATIENT PRESENTING CLINICAL SIGNS

Rosco Monk Diagnosed with Lyme disease in 2019 with seizure activity per owner at another clinic, resolved with Doxycycline. Thursday 9/30/22 patient collapsed and was acting disoriented, Friday owner brought to our clinic- neurologic, concerned for central nervous lesions, started on IV doxy and sent home with oral doxy and owner reports marked improvement yesterday-eating/drinking, walking normal.

SPECIES

Canine Abnormal PE/Chem/CBC/UA Results: C6 to lab pending

COMPUTED TOMOGRAPHY OF THE SKULL

BREED

A high resolution pre- and post-contrast CT study of the skull is provided for review.

Husky Mix

COMPUTED TOMOGRAPHIC FINDINGS

The pictured parts of the dentition are complete and unremarkable in all jaw quadrants.

SEX

The nasal cavity presents the expected aerated spaces between thin & even conchae and turbinates with smooth mucosal lining.

Male Neutered

The right zygomatic gland is moderately swollen and presents a heterogeneous contrast enhancement pattern with hypoattenuating intraparenchymal regions, accentuating the lobules of the zygomatic gland. The right ocular bulb is deviated dorsally and rostrally by the mass effect.

AGE

11 Years, 4 Months

Both temporomandibular joints present congruent joint spaces with even subchondral bone surfaces and are considered within normal limits.

INTERPRETED BY

Sebastian Schaub, DVM
Dr. med. vet. DipECVDI

Both tympanic bullae are aerated, the mucosal lining is not seen, the bony wall is smooth and thin. The external ear canals are within normal limits.

HOSPITAL NAME

Catskill Veterinary Services, PLLC

The brain presents no deviation from normal anatomy and symmetry. The brain parenchyma is homogeneous and within normal limits for attenuation and distribution of contrast enhancement. The ventricular system is non-dilated and symmetric.

The submandibular and medial retropharyngeal lymph nodes are small and elongated with a normal short-to-long-axis-ratio is < 0.5, the attenuation and contrast enhancement pattern is uniform.

COMPUTED TOMOGRAPHIC DIAGNOSIS

REFERRING VET

Dr. Daniela Carbone

- Small sialocele right zygomatic gland
- Right sided mild exophthalmos
- Normal brain

INVOICE

54390

INTERPRETATION OF THE FINDINGS & FURTHER RECOMMENDATIONS

In the present study of the brain there is no evidence of macromorphological disease, which supports the presumptive diagnosis of idiopathic epilepsy.

DATE

10-3-22

If not yet done so, the workup should be complemented by examination of CSF and complete bloodwork to screen for brain disease that is not necessarily associated with structural changes of the brain parenchyma and rule out hepatoencephalopathy and other systemic illness. In case of the strong clinical suspicion of structural intraparenchymal changes an MRI may be considered.

The sialocele of the right zygomatic gland might be an incidental finding at this point, but progressive fluid accumulation may cause more pronounced exophthalmos of the right ocular



PATIENT bulb.

Rosco Monk

SPECIES

Canine

BREED

Husky Mix

SEX

Male Neutered

AGE

11 Years, 4 Months

INTERPRETED BY

Sebastian Schaub, DVM
Dr. med. vet. DipECVDI

HOSPITAL NAME

Catskill Veterinary
Services, PLLC

REFERRING VET

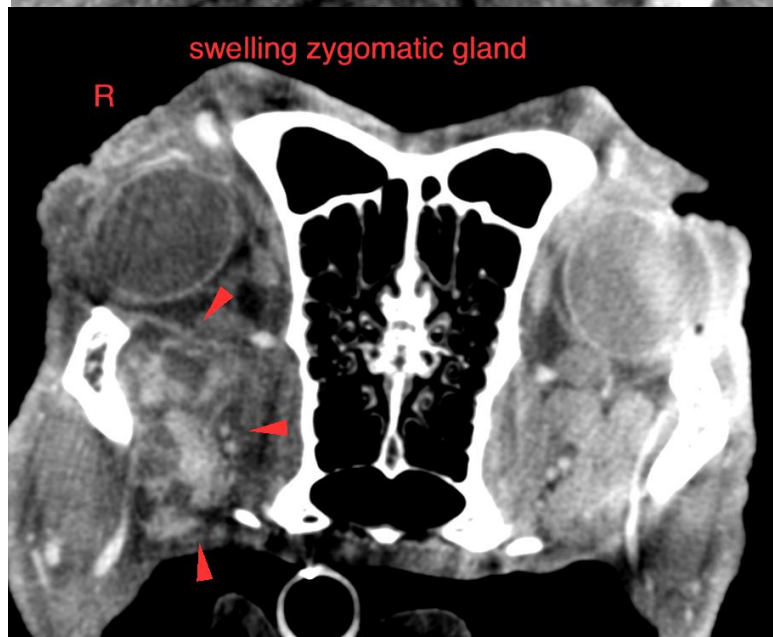
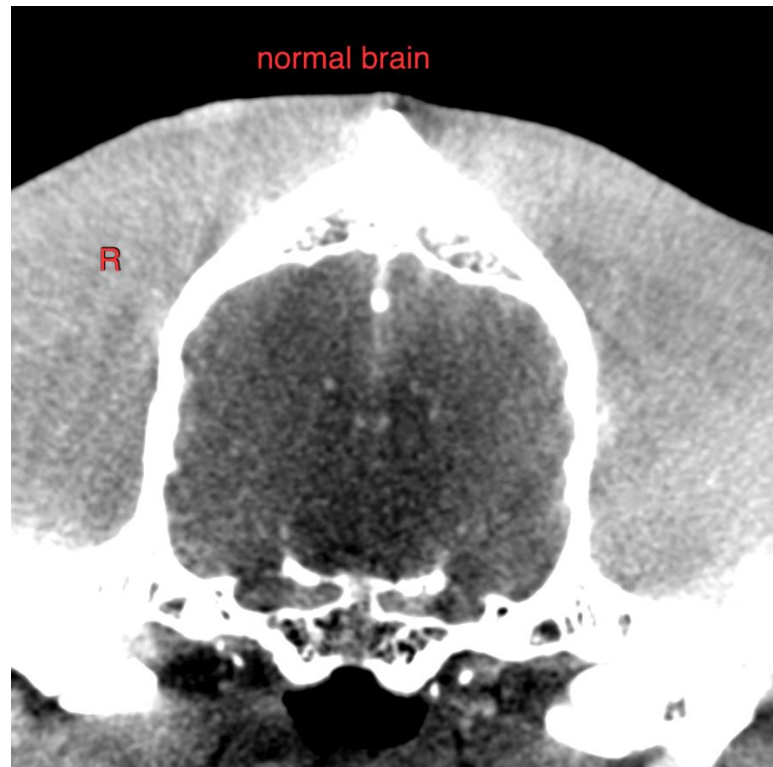
Dr. Daniela Carbone

INVOICE

54390

DATE

10-3-22





PATIENT

Rosco Monk

SPECIES

Canine

The information and recommendations provided are based on the images presented by the referring veterinarian/sonographer. No evaluation can be communicated regarding pathology that was not visible in the image/video clips provided.

BREED

Husky Mix

Thank you for this referral. If the clinical or image interpretation does not parallel your findings or if I can be of any further assistance please contact me.

Sebastian Schaub, Sebastian Schaub, DVM, Dr. med. vet. DipECVDI
sebast.schaub@gmail.com

SEX

Male Neutered

AGE

11 Years, 4 Months

INTERPRETED BY

Sebastian Schaub, DVM
Dr. med. vet. DipECVDI

HOSPITAL NAME

Catskill Veterinary
Services, PLLC

REFERRING VET

Dr. Daniela Carbone

INVOICE

54390

DATE

10-3-22