


**PATIENT PRESENTING CLINICAL SIGNS**

Mr. Hidey Ho Quirk Trying to determine if pet has been neutered or a cryptorchid male.  
 Abnormal PE/Chem/CBC/UA Results: Testosterone level 0.52 consistent with intact male

**SPECIES COMPUTED TOMOGRAPHY OF THE ABDOMEN**

Feline A high resolution pre- and post-contrast CT study of the abdomen is provided for review.

**COMPUTED TOMOGRAPHIC FINDINGS**

**BREED** The serosal fat presents normal attenuation behavior. There is no evidence of peritoneal effusion or peritonitis.

Savannah Both kidneys present within normal limits for size, shape and organ architecture. After contrast administration a bilaterally symmetric and uniform nephro- and pyelogram is noted.

**SEX** The testicles bilaterally are appreciated at the right & left lateral aspect of the urinary bladder respectively.

Intact Male The adrenal glands are within normal limits for size, shape and organ architecture.

**AGE** Both liver and spleen present with normal shape, even surface, uniformly attenuating parenchyma and homogeneous contrast enhancement, unremarkable.

2 Years The portal vein presents a normal order of its tributary veins and intrahepatic branching. No abnormal vessel is noted inside and outside of the liver parenchyma.

**INTERPRETED BY** The pancreas is evenly contoured, the pancreatic parenchyma is homogeneous and presents uniform contrast enhancement.

Sebastian Schaub, DVM Dr. med. vet. DipECVDI The position, delineation, wall and content of the gastrointestinal tract are considered within normal limits throughout.

**HOSPITAL NAME** The bony and surrounding soft tissue structures reveal no abnormalities.

**COMPUTED TOMOGRAPHIC DIAGNOSIS**

Mobile Pet Imaging CFL
 

- Bilateral abdominal cryptorchism

**REFERRING VET INTERPRETATION OF THE FINDINGS & FURTHER RECOMMENDATIONS**

Meaux The CT study is compatible with bilateral abdominal cryptorchism.

**INVOICE**

54388

**DATE**

10-3-22



**PATIENT**

Mr. Hidey Ho Quirk

**SPECIES**

Feline

**BREED**

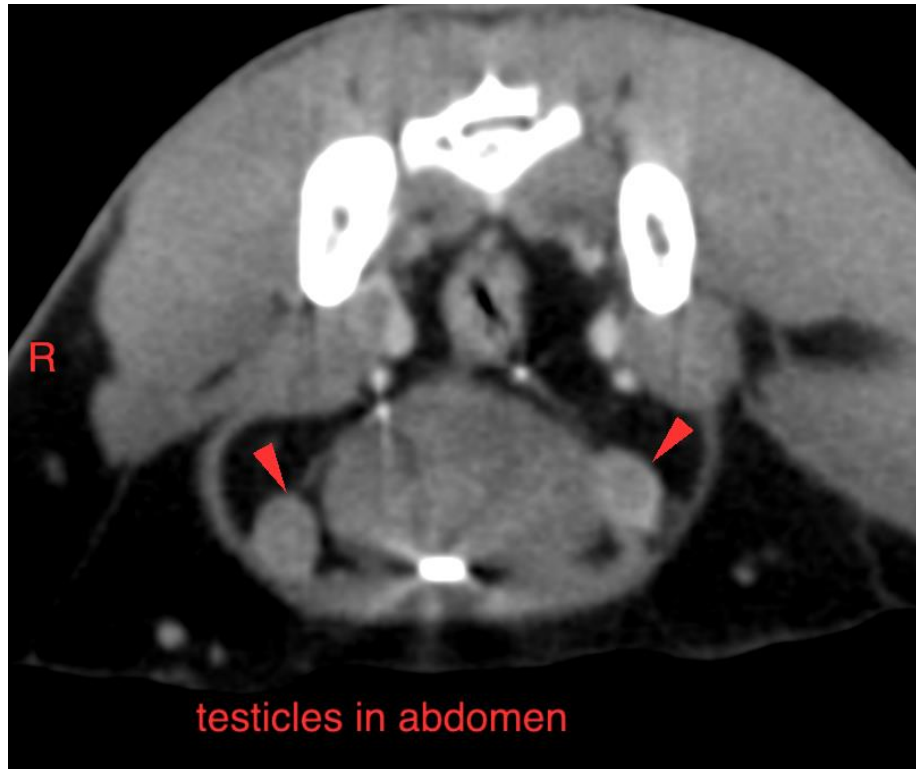
Savannah

**SEX**

Intact Male

**AGE**

2 Years



**INTERPRETED BY**

Sebastian Schaub, DVM  
Dr. med. vet. DipECVDI

**HOSPITAL NAME**

Mobile Pet Imaging  
CFL

**REFERRING VET**

Meaux

**INVOICE**

54388

**DATE**

10-3-22

The information and recommendations provided are based on the images presented by the referring veterinarian/sonographer. No evaluation can be communicated regarding pathology that was not visible in the image/video clips provided.

Thank you for this referral. If the clinical or image interpretation does not parallel your findings or if I can be of any further assistance please contact me.

**Sebastian Schaub**, Sebastian Schaub, DVM, Dr. med. vet. DipECVDI  
sebast.schaub@gmail.com