



PATIENT PRESENTING CLINICAL SIGNS

Lucy Reeves Acutely lame and non weight bearing Appears some digits are missing- No SX history. Was born with defect.

SPECIES RADIOGRAPHIC STUDY OF THE FRONT PAWS

Canine Radiographs of both front paws in two imaging planes are provided for review.

BREED RADIOGRAPHIC FINDINGS

Cocker Spaniel At the dorsal aspect of the distal epiphysis of the left radius and the dorsal aspect of the left radiocarpal bone moderate osteophyte new bone formation is appreciated. There is no evidence of soft tissue swelling level with the left carpal bone.

The osseous and soft tissue structures of the right carpal joint are within normal limits.

SEX The middle and distal phalanx of the third and fourth digit of the right front limb are absent; the respective metacarpal bones and proximal phalanx present a moderate decreased diameter.

SF Attached to the distal aspect of the main pad of the left front paw, a mineral opaque body is appreciated, measuring up to 8 mm in size.

AGE RADIOGRAPHIC DIAGNOSIS

- 16 Years
- Partial aphyalangia third and fourth digit right front limb with absent distal & middle phalanx
 - Degenerative osteoarthritis left antebrachiocarpal joint

INTERPRETED BY

Sebastian Schaub, DVM
Dr. med. vet. DipECVDI

INTERPRETATION OF THE FINDINGS & FURTHER RECOMMENDATIONS

The radiographic study of the front paws presents without specific abnormalities, explaining the acute front limb lameness. Rule that the foreign body attached to the main pad of the left front paw is a source for lameness.

HOSPITAL NAME

Golden Isles Animal Hospital

The congenital malformation of the right front paw is unlikely to cause acute lameness, but in case of contusion/distortion.

REFERRING VET

James Hornbuckle

INVOICE

54385

DATE

10-3-22



PATIENT

Lucy Reeves

SPECIES

Canine

BREED

Cocker Spaniel

SEX

SF

AGE

16 Years

INTERPRETED BY

Sebastian Schaub, DVM
Dr. med. vet. DipECVDI

HOSPITAL NAME

Golden Isles Animal
Hospital

REFERRING VET

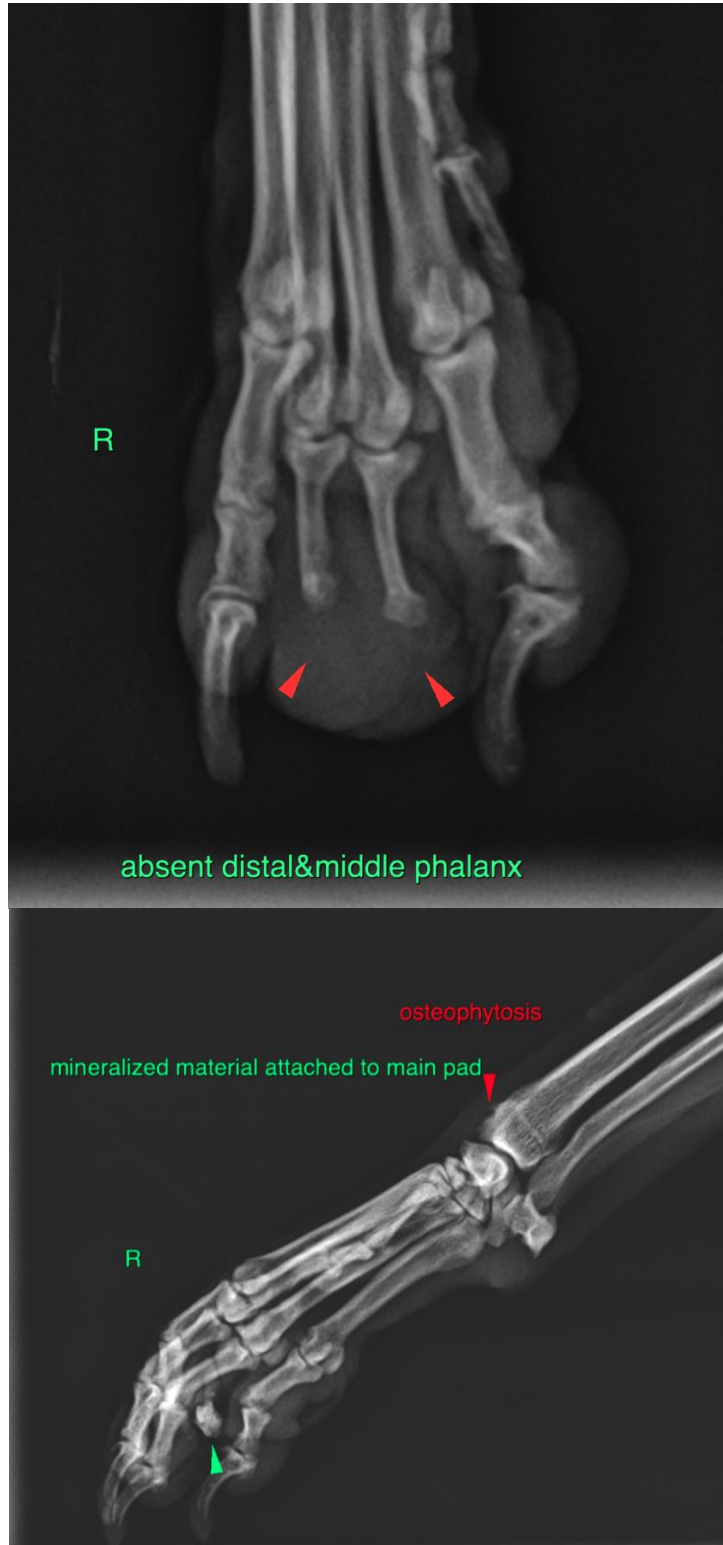
James Hornbuckle

INVOICE

54385

DATE

10-3-22





PATIENT

Lucy Reeves

The information and recommendations provided are based on the images presented by the referring veterinarian/sonographer. No evaluation can be communicated regarding pathology that was not visible in the image/video clips provided.

Thank you for this referral. If the clinical or image interpretation does not parallel your findings or if I can be of any further assistance please contact me.

SPECIES

Canine

Sebastian Schaub, Sebastian Schaub, DVM, Dr. med. vet. DipECVDI
sebast.schaub@gmail.com

BREED

Cocker Spaniel

SEX

SF

AGE

16 Years

INTERPRETED BY

Sebastian Schaub, DVM
Dr. med. vet. DipECVDI

HOSPITAL NAME

Golden Isles Animal
Hospital

REFERRING VET

James Hornbuckle

INVOICE

54385

DATE

10-3-22