

**PATIENT**

Sadie Watterund

PRESENTING CLINICAL SIGNS

P presented with Painful front right shoulder.
Abnormal PE/Chem/CBC/UA Results:

SPECIES

Canine

COMPUTED TOMOGRAPHY OF THE ELBOW JOINTS

A high resolution plain CT study of the elbow joints is provided for review.

BREED

Husky mix

COMPUTED TOMOGRAPHIC FINDINGS

The periarticular bones of both elbow joints present mild osteophyte new bone formation and the tip of the medial coronoid process bilaterally is mildly irregular.

SEX

Female Spayed

The right distal humeral metaphysis presents an ill-defined zone of permeative osteolytic lesions extending up into the distal right humeral diaphysis with perforation of the cortex of the medial aspect of the supratrochlear foramen and advanced brush-border periosteal new bone formation. Patchy sclerosis of the medullary cavity of the right humerus is seen at the same level as well. A focal mild to moderate soft tissue swelling is visible at the same level.

AGE

13 Years

COMPUTED TOMOGRAPHIC DIAGNOSIS

- Monostotic aggressive mixed osteolytic and osteoproliferative lesion right distal humerus
- Bilateral very mild degenerative osteoarthritis of the elbow joints

INTERPRETED BY

Sebastian Schaub, DVM
Dr. med. vet. DipECVDI

INTERPRETATION OF THE FINDINGS & FURTHER RECOMMENDATIONS

The findings are compatible with primary osseous neoplasia – such as osteosarcoma, chondrosarcoma, fibrosarcoma, lymphosarcoma, hemangiosarcoma, other – due to the unusual location metastasis needs to be considered as well. Theoretically osteomyelitis (e.g. mycotic) is a consideration as well. FNA sampling or bone biopsy (might increase risk for pathological fracture) can be used to confirm the diagnosis., Consider full tumor staging. Amputation might be considered as treatment option.

HOSPITAL NAME

State Avenue Vet
Clinic

REFERRING VET

Dr. Raul Casas-Dolz

INVOICE

48086

DATE

10-28-21



PATIENT

Sadie Watterund

SPECIES

Canine

BREED

Husky mix

SEX

Female Spayed

AGE

13 Years

INTERPRETED BY

Sebastian Schaub, DVM
Dr. med. vet. DipECVDI

HOSPITAL NAME

State Avenue Vet
Clinic

REFERRING VET

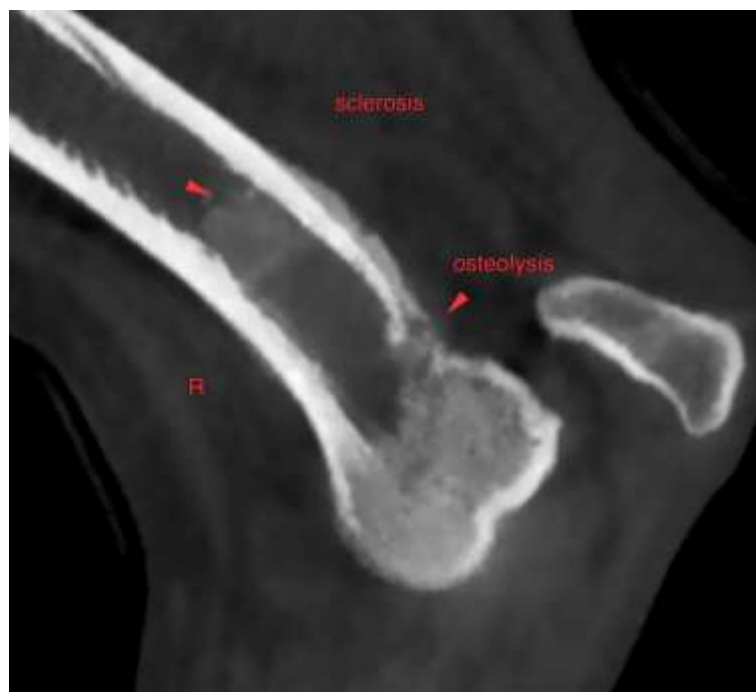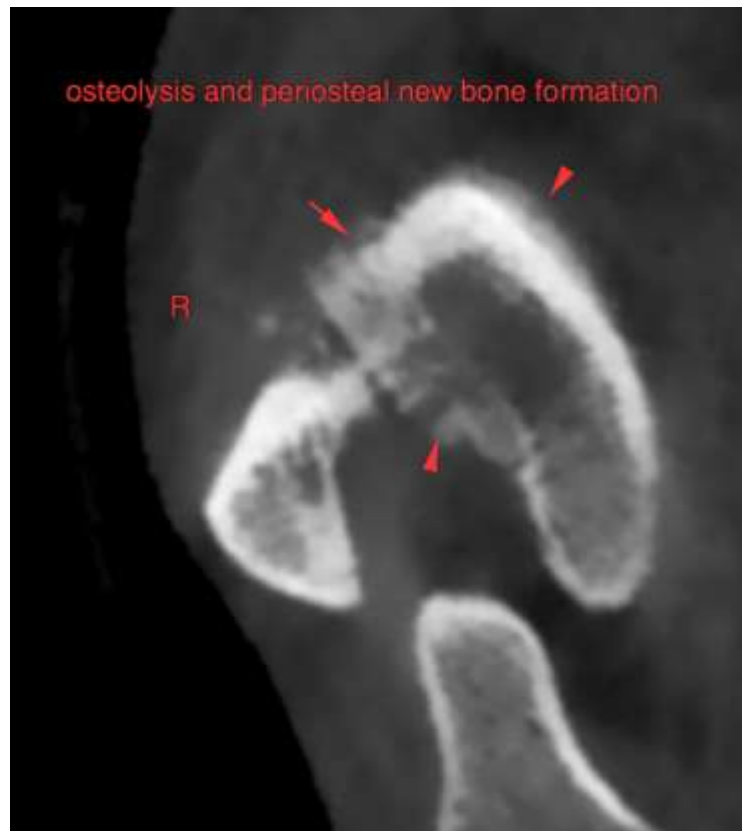
Dr. Raul Casas-Dolz

INVOICE

48086

DATE

10-28-21





PATIENT

Sadie Watterund

SPECIES

Canine

The information and recommendations provided are based on the images presented by the referring veterinarian. No evaluation can be communicated regarding pathology that was not visible in the image/video clips provided.

BREED

Husky mix

Thank you for this referral. If the clinical or image interpretation does not parallel your findings or if I can be of any further assistance please contact me.

Sebastian Schaub, Sebastian Schaub, DVM, Dr. med. vet. DipECVDI
sebast.schaub@gmail.com

SEX

Female Spayed

AGE

13 Years

INTERPRETED BY

Sebastian Schaub, DVM
Dr. med. vet. DipECVDI

HOSPITAL NAME

State Avenue Vet
Clinic

REFERRING VET

Dr. Raul Casas-Dolz

INVOICE

48086

DATE

10-28-21