

**PATIENT**

Monster Yates

**PRESENTING CLINICAL SIGNS**

Increased cough; Upon PE, newly diagnosed heart murmur 4/6; Clear lungs upon auscultation; incidental findings, possible bladder stones.

**SPECIES**

Canine

**RADIOGRAPHIC STUDY OF THE THORAX**

Radiographs of the thorax in three imaging planes are provided for review.

**BREED**

Chihuahua

**RADIOGRAPHIC FINDINGS**

The surrounding bony structures are within normal limits.

**SEX**

F

The heart is of normal size and shape, there is no evidence of cardiac chamber or vascular enlargement.

**AGE**

10 Years

The cranial mediastinum presents the expected soft tissue opacity. The mediastinal width is less than twice the width of the vertebral column at the same level.

The trachea is normal in diameter and presents the anticipated course. The luminal outline of the trachea is smooth.

**INTERPRETED BY**

Sebastian Schaub, DVM  
Dr. med. vet. DipECVDI

Throughout all lung lobes, variable sized, well-defined, soft tissue opaque nodular lesions are visible, measuring up to 11 mm in size.

The diaphragm is well delineated with even surface and the expected mild cranial bulging of the diaphragmatic cupola.

**HOSPITAL NAME**

Paws and Claws  
Urgent Care

**RADIOGRAPHIC DIAGNOSIS**

- Structured nodular interstitial lung pattern
- Non-specific subcutaneous nodules

**REFERRING VET**

Dr. Juarez

**INTERPRETATION OF THE FINDINGS & FURTHER RECOMMENDATIONS**

The nodular lung pattern is highly concerning for pulmonary metastatic lung disease. Granulomatous disease might be a consideration, but I would expect evidence of accompanying lymphadenopathy. Ultrasound guided FNA sampling of the larger nodule level with the 4<sup>th</sup> right intercostal space might be feasible for further evaluation. Consider screening for primary neoplasia in other locations.

**INVOICE**

48090

**DATE**

10-28-21



**PATIENT**

Monster Yates

**SPECIES**

Canine

**BREED**

Chihuahua

**SEX**

F

**AGE**

10 Years

**INTERPRETED BY**

Sebastian Schaub, DVM  
Dr. med. vet. DipECVDI

**HOSPITAL NAME**

Paws and Claws  
Urgent Care

**REFERRING VET**

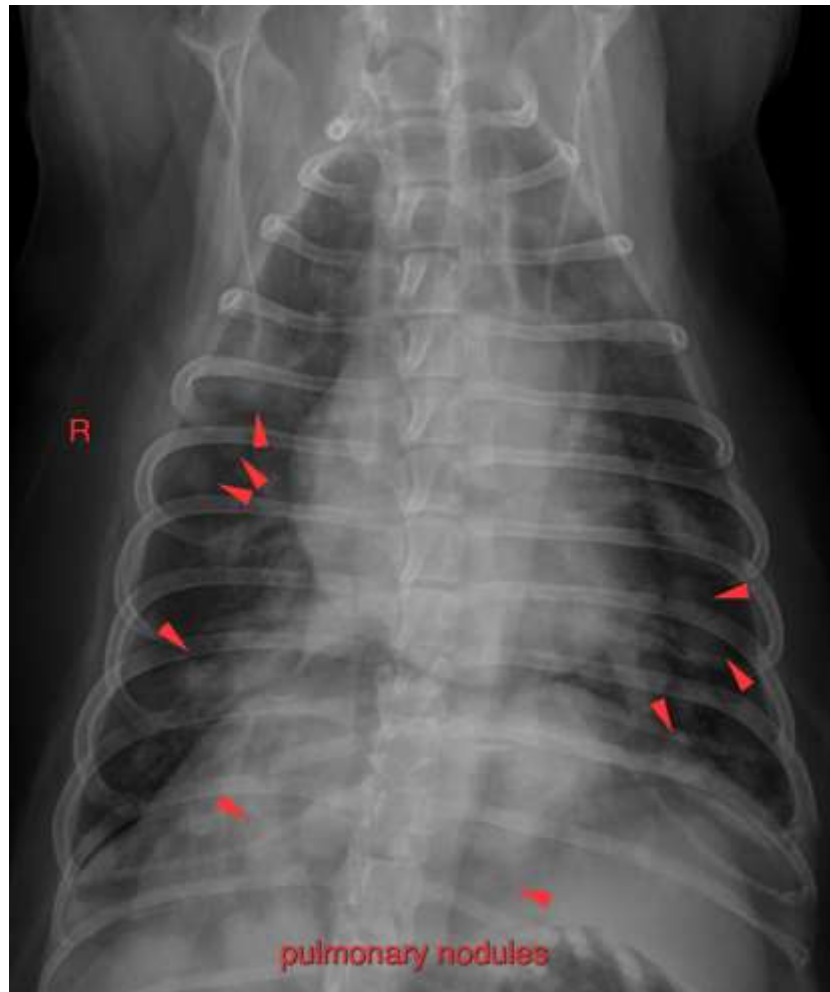
Dr. Juarez

**INVOICE**

48090

**DATE**

10-28-21



The information and recommendations provided are based on the images presented by the referring veterinarian. No evaluation can be communicated regarding pathology that was not visible in the image/video clips provided.

Thank you for this referral. If the clinical or image interpretation does not parallel your findings or if I can be of any further assistance please contact me.

**Sebastian Schaub**, Sebastian Schaub, DVM, Dr. med. vet. DipECVDI  
sebast.schaub@gmail.com