


PATIENT PRESENTING CLINICAL SIGNS

Camo Epps

Reason for Visit: COUGHING History: P IS A 12Y2M OLD INTACT MALE RETRIEVER MIX PRESENTING TODAY FOR COUGHING. COUGH GETTING WORSE OVER PAST 6 MONTHS. O STATES IT ONLY USED TO HAPPEN AFTER DRINKING WATER NOW HAPPENS MORE FREQUENT AND RANDOMLY. P HAS LOST WEIGHT. P STILL EATING BUT NOT AS WELL AS NORMAL. P BEGAN COUGHING ON SCALE THEN COLLAPSED ON FLOOR. GUMS VERY PALE GOT UP COUPLE MINUTES LATER

SPECIES

Canine

RADIOGRAPHIC STUDY OF THE THORAX
BREED

Radiographs of the thorax in two imaging planes are provided for review.

Retriever X

RADIOGRAPHIC FINDINGS
SEX

Multifocal moderate spondylosis formation is seen along the thoracic spine. The costal cartilages present moderate degenerative changes.

Male

The extrathoracic soft tissues present homogeneous without abnormalities.

AGE

The heart is of normal size and shape, there is no evidence of cardiac chamber or vascular enlargement. The pulmonary vasculature is within normal limits.

12 Years 2 Months

The cranial mediastinum presents the expected soft tissue opacity. The mediastinal width is less than twice the width of the vertebral column at the same level.

INTERPRETED BY

 Sebastian Schaub,
 DVM Dr. med. vet.
 DipECVDI

The trachea is normal in diameter and presents the anticipated course. The luminal outline of the trachea is smooth.

The bronchial tree presents with thin walls and tapers uniformly towards the periphery as expected.

The lung parenchyma presents the expected architecture and opacity; the intrapulmonary vascular branching is seen up to the third order lung vessels.

HOSPITAL NAME

DPC Vet Hospital

The diaphragm is well delineated with even surface and the expected mild cranial bulging of the diaphragmatic cupola.

REFERRING VET

Dr. Rivera

RADIOGRAPHIC DIAGNOSIS

- Spondylosis deformans
- Degenerative changes costal cartilages
- No evidence of pulmonary pathology

INVOICE

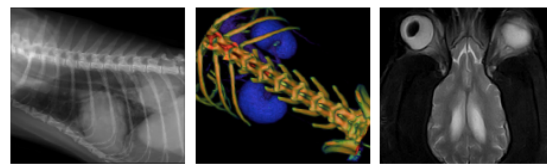
26721

INTERPRETATION OF THE FINDINGS & FURTHER RECOMMENDATIONS

The radiographic study of the thorax is negative for clinically relevant pathology. Rule out cardiac arrhythmia as source for the described clinical signs.

DATE

10/28/21



PATIENT The information and recommendations provided are based on the images presented by the referring veterinarian. No evaluation can be communicated regarding pathology that was not visible in the image/video clips provided.

Camo Epps

SPECIES

Thank you for this referral. If the clinical or image interpretation does not parallel your findings or if I can be of any further assistance please contact me.

Canine

Sebastian Schaub, Sebastian Schaub, DVM, Dr. med. vet. DipECVDI
sebast.schaub@gmail.com

BREED

Retriever X

SEX

Male

AGE

12 Years 2 Months

INTERPRETED BY

Sebastian Schaub,
DVM Dr. med. vet.
DipECVDI

HOSPITAL NAME

DPC Vet Hospital

REFERRING VET

Dr. Rivera

INVOICE

26721

DATE

10/28/21