



PATIENT

Biscuit Simpson

PRESENTING CLINICAL SIGNS

Biscuit is indoor/outdoor w/ a doggie door. PP went away yesterday and came back today to find him injured. She thinks it happened last night b/c he didn't eat his dinner. He is healthy otherwise and is current on vaccines.

SPECIES

Feline

COMPUTED TOMOGRAPHY OF THE THORAX AND ABDOMEN

A high resolution pre- and post-contrast CT study of the thorax and abdomen are provided for review.

BREED

DSH

COMPUTED TOMOGRAPHIC FINDINGS

Thorax

SEX

MN

In the subcutaneous tissue along the dorsal and left lateral aspect of the thoracic wall and cranial abdominal wall, multiple gas inclusions are visible, and the subcutaneous fat presents mild fat-stranding.

AGE

2 Years

The sternal, cranial mediastinal and tracheobronchial lymph nodes are small elongated with a normal short-to-long-axis-ratio is < 0.5, the attenuation and contrast enhancement pattern is uniform and considered within normal limits.

The cardiovascular structures including the pulmonary vasculature are within normal limits.

INTERPRETED BY

Sebastian Schaub, DVM
Dr. med. vet. DipECVDI

The bronchial tree presents with regular branching and tapers uniformly towards the periphery as expected, the bronchial walls are thin and smooth. The bronchus-to-artery ratio is within normal limits.

The lung parenchyma presents the expected architecture and attenuation behavior.

HOSPITAL NAME

Suncoast Veterinary

Small incidental gas pockets are seen within the esophageal lumen, there is no evidence of abnormal dilation.

Abdomen

REFERRING VET

Dr. Young

The serosal fat presents normal attenuation behavior. There is no evidence of peritoneal effusion or peritonitis.

Both kidneys present within normal limits for size, shape and organ architecture. After contrast administration a bilaterally symmetric and uniform nephro- and pyelogram is noted.

INVOICE

48063

The adrenal glands are within normal limits for size, shape and organ architecture.

Both liver and spleen present with normal shape, even surface, uniformly attenuating parenchyma and homogeneous contrast enhancement, unremarkable.

DATE

10-28-21

The pancreas is evenly contoured, the pancreatic parenchyma is homogeneous and presents uniform contrast enhancement.

**PATIENT**

The position, delineation, wall and content of the gastrointestinal tract are considered within normal limits throughout.

Biscuit Simpson

Mild fat-stranding of the subcutaneous fat is seen in the perineal region.

SPECIES

Feline

Multiple gas inclusions are seen level with the right tarsal joint. The talocrural joint is luxated dorsally, proximally and laterally. The fibula is intact with moderate bending in the distal segment. Medial to the lateral malleolus, a small isolated osseous lamella measuring 5.7 x 1.6 x 6.4 mm size is visible. Multiple smaller osseous fragments are seen in the periphery of the talocrural joint. The osseous structures of the tarsus are intact.

BREED

DSH

COMPUTED TOMOGRAPHIC DIAGNOSIS**SEX**

MN

- Open traumatic luxation of the right talocrural joint with multiple small avulsion fragments the fibula is intact
- Mild subcutaneous emphysema thoracic and abdominal wall
- Normal intrathoracic structures
- Normal intraabdominal structures

AGE

2 Years

INTERPRETATION OF THE FINDINGS & FURTHER RECOMMENDATIONS

The findings are compatible with the history of preceding trauma and an open luxation of the right talocrural joint with an intact lateral malleolus and fibula. Multiple small avulsion fragments are seen in the peripheral of the talocrural joint. Discussing the chances of surgical stabilization with an orthopedic surgeon is recommended.

INTERPRETED BY

Sebastian Schaub, DVM
Dr. med. vet. DipECVDI

The thorax and abdomen present without gross pathology but the emphysema suggestive for cutaneous laceration.

HOSPITAL NAME

Suncoast Veterinary

REFERRING VET

Dr. Young

INVOICE

48063

DATE

10-28-21



PATIENT

Biscuit Simpson

SPECIES

Feline

BREED

DSH

SEX

MN

AGE

2 Years

INTERPRETED BY

Sebastian Schaub, DVM
Dr. med. vet. DipECVDI

HOSPITAL NAME

Suncoast Veterinary

REFERRING VET

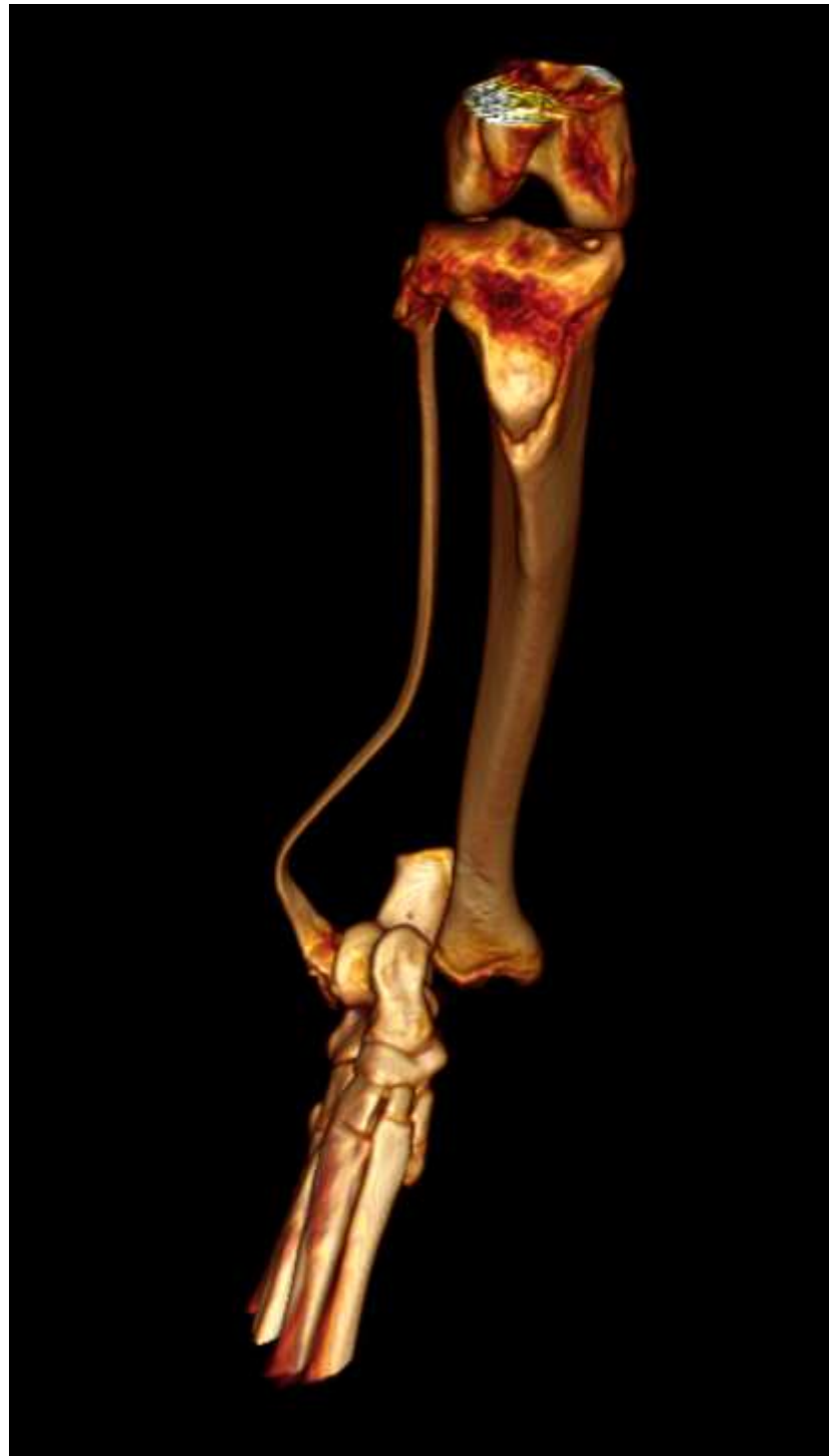Dr. Young

INVOICE

48063

DATE

10-28-21





PATIENT

Biscuit Simpson

SPECIES

Feline

BREED

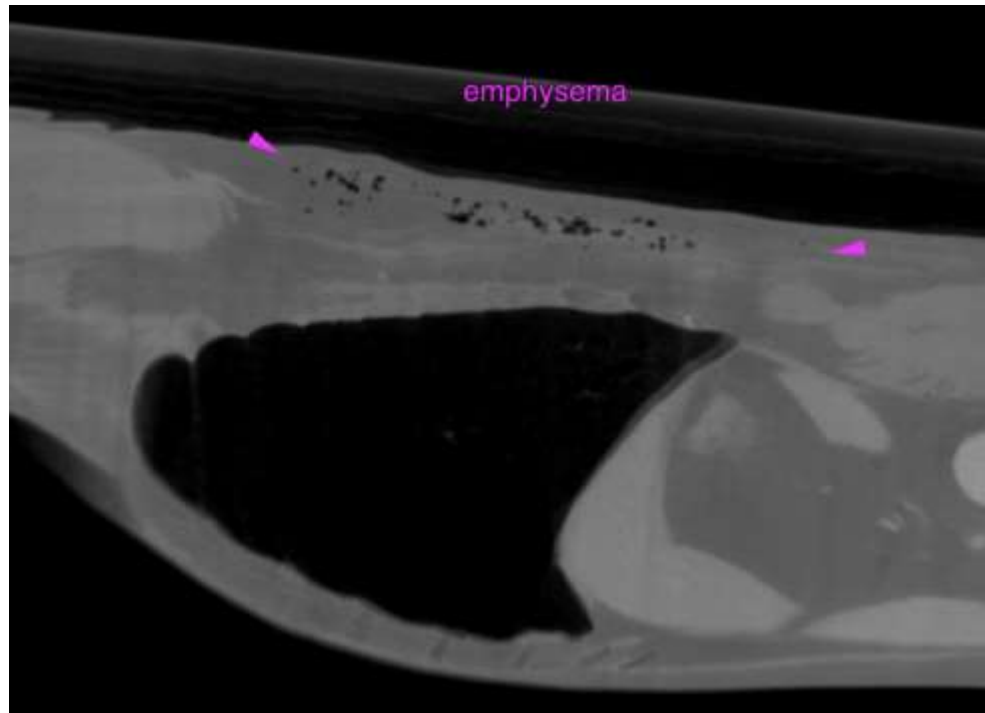
DSH

SEX

MN

AGE

2 Years



INTERPRETED BY

Sebastian Schaub, DVM
Dr. med. vet. DipECVDI

HOSPITAL NAME

Suncoast Veterinary

REFERRING VET

Dr. Young

INVOICE

48063

DATE

10-28-21

The information and recommendations provided are based on the images presented by the referring veterinarian. No evaluation can be communicated regarding pathology that was not visible in the image/video clips provided.

Thank you for this referral. If the clinical or image interpretation does not parallel your findings or if I can be of any further assistance please contact me.

Sebastian Schaub, Sebastian Schaub, DVM, Dr. med. vet. DipECVDI
sebast.schaub@gmail.com