

**PATIENT PRESENTING CLINICAL SIGNS**

Dolce Shaff History: *DVM pet. Left forelimb lameness localized to the shoulder joint.
Abnormal PE/Chem/CBC/UA Results:

SPECIES COMPUTED TOMOGRAPHIC STUDY OF THE FRONT LIMBS

Canine A high resolution pre- and post-contrast CT study of the front limbs are provided for review.

COMPUTED TOMOGRAPHIC FINDINGS**BREED**

Shih Tzu Mix The periarticular bones of both shoulder joints present mild osteophyte new bone formation. In the bicipital groove of the left humerus, mild to moderate exostosis formation is appreciated.

SEX

Neutered Male The left spinal nerve T1 is moderately thickened, starting approximately level with the left neuroforamen T1/T2 and can be appreciated up into the axillary region, measuring up to 5.5 mm in diameter. Post contrast administration, the thickened left spinal nerve T1 has a heterogeneous contrast enhancement pattern.

AGE

12 Years 6 Months Both elbow joints present smooth osseous margins, the medial coronoid process of both elbow joints is well-defined and has a homogeneous density. The soft tissue structures surrounding the elbow joints are unremarkable.

COMPUTED TOMOGRAPHIC DIAGNOSIS**INTERPRETED BY**

- Segmental neuropathy left spinal nerve T1, starting level with the respective neuroforamen
- Mild degenerative osteoarthritis shoulder joints bilaterally with mild exostosis formation of the bicipital groove

Sebastian Schaub, DVM
Dr. med. vet. DipECVDI

HOSPITAL NAME

Mobile Pet Imaging

INTERPRETATION OF THE FINDINGS & FURTHER RECOMMENDATIONS

The thickened left spinal nerve T1 is highly suggestive for peripheral malignant nerve sheath tumor. A potential is neuritis. The finding is a plausible explanation for the left front limb lameness. The thickened spinal nerve appears to be extending up to the left neuroforamen T1/T2 – if surgery is an option here, MRI might be used to evaluate possible extend of the thickened spinal nerve into the vertebral canal; no mass effect on the dural tube can be appreciated by CT.

REFERRING VET

Meaux

INVOICE

17933

DATE

10/27/22



PATIENT

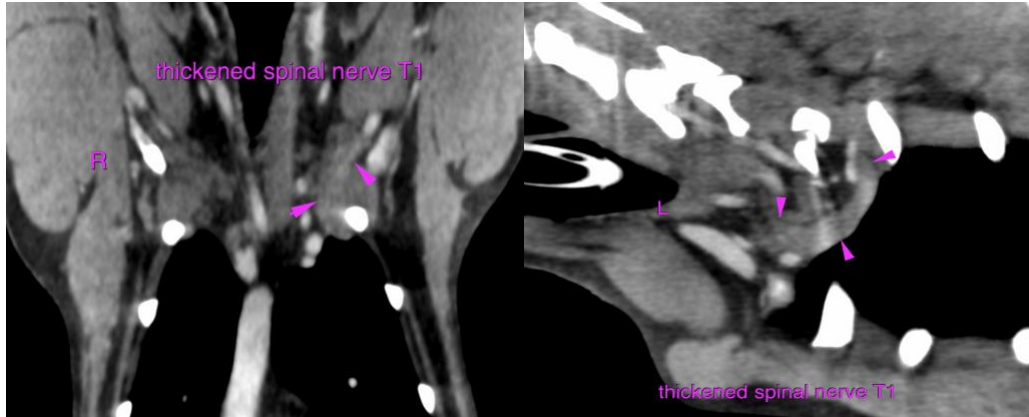
Dolce Shaff

SPECIES

Canine

BREED

Shih Tzu Mix



SEX

Neutered Male

AGE

12 Years 6 Months

The information and recommendations provided are based on the images presented by the referring veterinarian/sonographer. No evaluation can be communicated regarding pathology that was not visible in the image/video clips provided.

Thank you for this referral. If the clinical or image interpretation does not parallel your findings or if I can be of any further assistance please contact me.

Sebastian Schaub, Sebastian Schaub, DVM, Dr. med. vet. DipECVDI
sebast.schaub@gmail.com

INTERPRETED BY

Sebastian Schaub, DVM
Dr. med. vet. DipECVDI

HOSPITAL NAME

Mobile Pet Imaging

REFERRING VET

Meaux

INVOICE

17933

DATE

10/27/22