



PATIENT

Casey Powell

PRESENTING CLINICAL SIGNS

boney mass on skull. 0.6 cm x 0.6 cm firm, non-mobile mass between eyes located on skull between eyes. The mass was initially noticed 2 weeks ago; no progression. Mass does not cause discomfort. CT performed of head and thorax

SPECIES

Canine

COMPUTED TOMOGRAPHY OF THE SKULL & THORAX

A pre- and post-contrast CT study of the skull and thorax in a bone, lung and soft tissue reconstruction are provided for review.

BREED

Labrador Retriever

COMPUTED TOMOGRAPHIC FINDINGS

Skull

The pictured parts of the dentition are complete and unremarkable in all jaw quadrants.

SEX

The nasal cavity presents the expected aerated spaces between thin & even conchae and turbinates with smooth mucosal lining.

M

Protruding from the caudodorsal aspect of the most caudal aspect of the left nasal bone presents a small (4.7 x 6.1 x 5.2 mm), amorphous mineralizing mass with focal osteolysis of the nasal bone.

AGE

Both temporomandibular joints present congruent joint spaces with even subchondral bone surfaces and are considered within normal limits.

1 Year

Both tympanic bullae are aerated, the mucosal lining is not seen, the bony wall is smooth and thin. The external ear canals are within normal limits.

INTERPRETED BY

Sebastian Schaub, DVM
Dr. med. vet. DipECVDI

The brain presents no deviation from normal anatomy and symmetry. The brain parenchyma is homogeneous and within normal limits for attenuation and distribution of contrast enhancement. The ventricular system is non-dilated and symmetric.

HOSPITAL NAME

Animal Health
Partners

The submandibular and medial retropharyngeal lymph nodes are small and elongated with a normal short-to-long-axis-ratio is < 0.5, the attenuation and contrast enhancement pattern is uniform.

The osseous and soft tissue structures of the neck are within normal limits.

Thorax

REFERRING VET

Dr. Jeffery Biskup

The bony and surrounding soft tissue structures are within normal limits.

The sternal, cranial mediastinal and tracheobronchial lymph nodes are small elongated with a normal short-to-long-axis-ratio is < 0.5, the attenuation and contrast enhancement pattern is uniform and considered within normal limits.

INVOICE

54829

The cardiovascular structures including the pulmonary vasculature are within normal limits.

The bronchial tree presents with regular branching and tapers uniformly towards the periphery as expected, the bronchial walls are thin and smooth. The bronchus-to-artery ratio is within normal limits.

DATE

10-27-22

The lung parenchyma presents the expected architecture and attenuation behavior.

Small incidental gas pockets are seen within the esophageal lumen, there is no evidence of



PATIENT abnormal dilation.

Casey Powell

COMPUTED TOMOGRAPHIC DIAGNOSIS

- Monostotic semiaggressive osteoproliferative small mass left nasal bone
- Normal thorax, no evidence of pulmonary metastatic disease

SPECIES

Canine

INTERPRETATION OF THE FINDINGS & FURTHER RECOMMENDATIONS

The small osteoproliferative lesion at the caudodorsal aspect of the nasal bone can present a benign lesion such as chondroid osteoma, small chondroma, focal osteitis or early stage of biologically more aggressive lesion such as early stage of chondrosarcoma, osteosarcoma. Recommend FNA sampling or biopsy for further differentiation. Complete surgical excision of the mass appears feasible.

BREED

Labrador Retriever

SEX

M

AGE

1 Year

INTERPRETED BY

Sebastian Schaub, DVM
Dr. med. vet. DipECVDI

HOSPITAL NAME

Animal Health
Partners

REFERRING VET

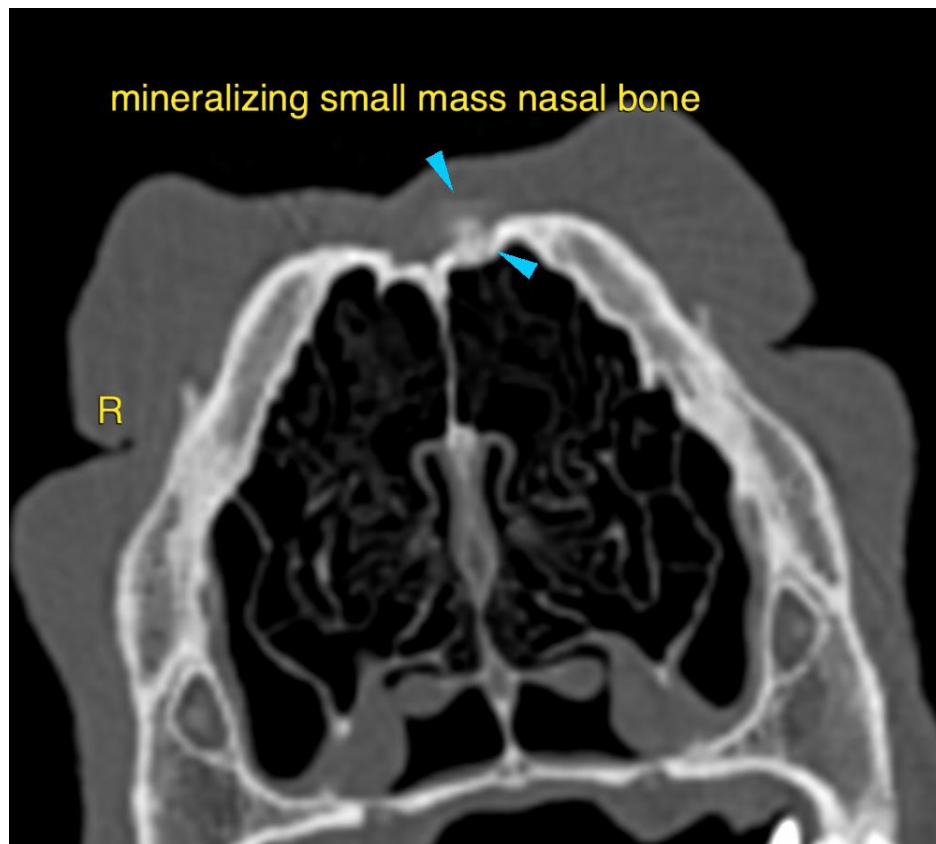
Dr. Jeffery Biskup

INVOICE

54829

DATE

10-27-22





PATIENT

Casey Powell

SPECIES

Canine

BREED

Labrador Retriever

SEX

M

AGE

1 Year

INTERPRETED BY

Sebastian Schaub, DVM
Dr. med. vet. DipECVDI

HOSPITAL NAME

Animal Health
Partners

REFERRING VET

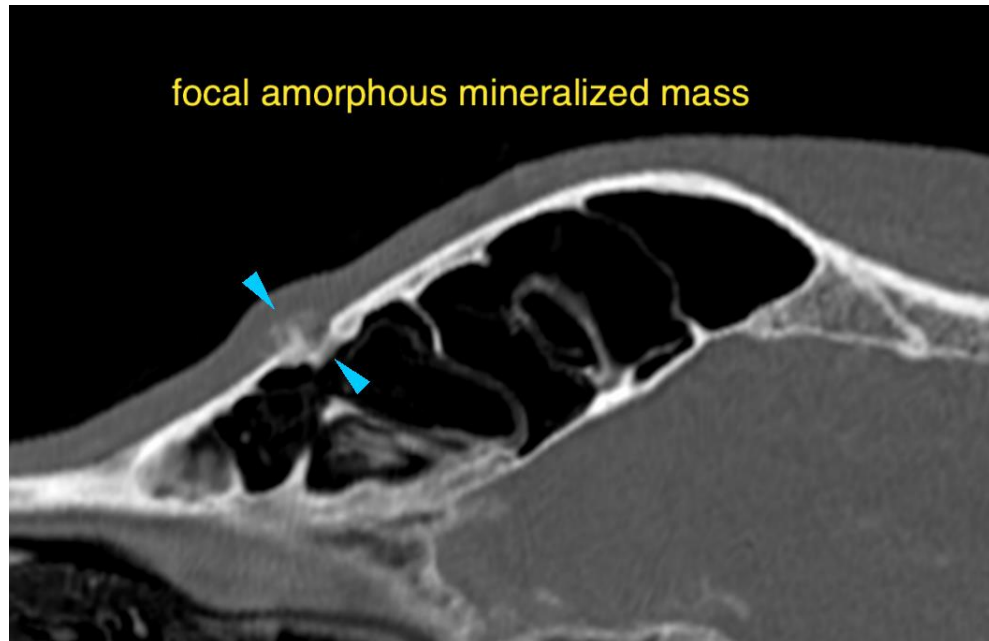
Dr. Jeffery Biskup

INVOICE

54829

DATE

10-27-22



The information and recommendations provided are based on the images presented by the referring veterinarian/sonographer. No evaluation can be communicated regarding pathology that was not visible in the image/video clips provided.

Thank you for this referral. If the clinical or image interpretation does not parallel your findings or if I can be of any further assistance please contact me.

Sebastian Schaub, Sebastian Schaub, DVM, Dr. med. vet. DipECVDI
sebast.schaub@gmail.com