

**PATIENT**

Capone Sarsfield

PRESENTING CLINICAL SIGNS

Patient started vomiting this morning, abdominal radiographs sent to radiologist reported 'highly concerning for gastric foreign material (such as paper or bedding), given the degree of gastric distention, a pyloric outflow obstruction is likely, although severe gastritis is also a possibility'.

SPECIES

Canine

Patient was brought into an endoscopy which revealed a large amount of foam, inflammation/irritation/ulceration of stomach but no foreign material in esophagus, stomach, or cranial duodenum. CT taken immediately following endoscopy to rule out foreign material having passed into the lower GI tract between radiographs and endoscopy.

BREED

Pitbull

COMPUTED TOMOGRAPHY OF THE ABDOMEN

A high resolution plain CT study of the abdomen is provided for review.

COMPUTED TOMOGRAPHIC FINDINGS

Only additional findings to the report dated 10/27/22 are addressed.

SEX

Male Neutered

The stomach is moderately distended by gas and foamy fluid attenuating material. The gastric wall appears prominent.

AGE

6 Years, 11 Months

The position, delineation and content of the intestinal tract are considered within normal limits throughout.

No additional findings are appreciated.

INTERPRETED BY

Sebastian Schaub, DVM
Dr. med. vet. DipECVDI

COMPUTED TOMOGRAPHIC DIAGNOSIS

- Gas and fluid distended stomach ± mural thickening of the wall
- Prostatomegaly with dystrophic mineralization, stationary
- Lymphadenopathy medial iliac lymph nodes
- Degenerative osteoarthritis coxofemoral joints bilaterally
- Spondylosis deformans

HOSPITAL NAME

Catskill Veterinary
Services, PLLC

INTERPRETATION OF THE FINDINGS & FURTHER RECOMMENDATIONS

The current CT study of the abdomen presents without signs of gastrointestinal mechanical obstruction. The gas distended stomach is considered as a sequela to preceding gastroscopy. The material appreciated in the stomach in combination with the presenting clinical signs can indicate functional gastric emptying disorder due to gastritis, explaining the suspected thickening of the gastric wall.

REFERRING VET

Dr. Joseph
D'Abbraccio

INVOICE

54849

DATE

10-27-22



PATIENT

Capone Sarsfield

SPECIES

Canine

BREED

Pitbull

SEX

Male Neutered

AGE

6 Years, 11 Months

INTERPRETED BY

Sebastian Schaub, DVM
Dr. med. vet. DipECVDI

HOSPITAL NAME

Catskill Veterinary
Services, PLLC

REFERRING VET

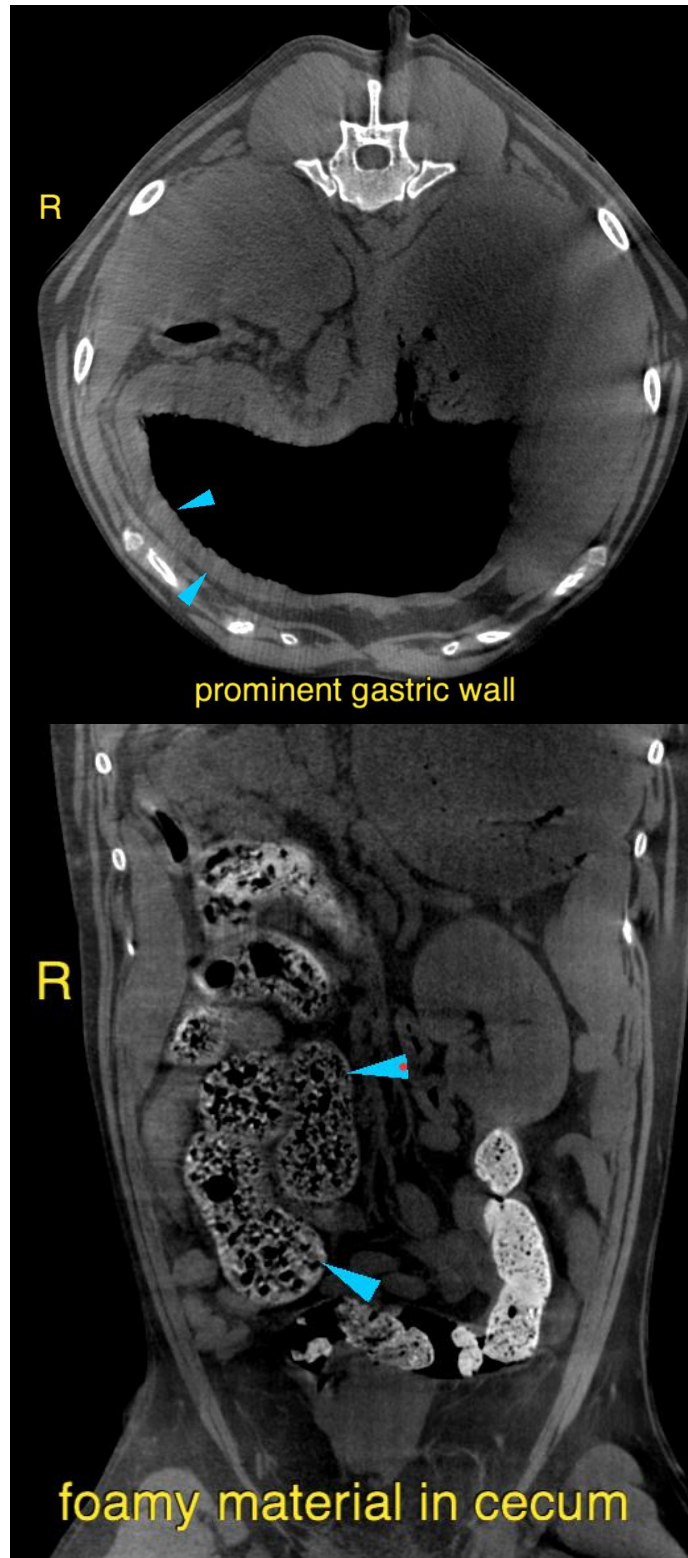
Dr. Joseph
D'Abbraccio

INVOICE

54849

DATE

10-27-22





PATIENT

Capone Sarsfield

The information and recommendations provided are based on the images presented by the referring veterinarian/sonographer. No evaluation can be communicated regarding pathology that was not visible in the image/video clips provided.

SPECIES

Canine

Thank you for this referral. If the clinical or image interpretation does not parallel your findings or if I can be of any further assistance please contact me.

Sebastian Schaub, Sebastian Schaub, DVM, Dr. med. vet. DipECVDI
sebast.schaub@gmail.com

BREED

Pitbull

SEX

Male Neutered

AGE

6 Years, 11 Months

INTERPRETED BY

Sebastian Schaub, DVM
Dr. med. vet. DipECVDI

HOSPITAL NAME

Catskill Veterinary
Services, PLLC

REFERRING VET

Dr. Joseph
D'Abbraccio

INVOICE

54849

DATE

10-27-22