



PATIENT

Annie Matros

PRESENTING CLINICAL SIGNS

Right axillary mass / right shoulder mass

COMPUTED TOMOGRAPHY OF THE FRONT LIMBS

SPECIES

Canine

A high resolution post-contrast CT study of the front limbs is provided for review.

BREED

Wheaten Terrier

COMPUTED TOMOGRAPHIC FINDINGS

The periarticular bones of the left shoulder joint present mild osteophyte new bone formation, mild exostosis formation is seen in the bicipital groove of the left humerus. The right shoulder joint presents smooth margins of the osseous structures. The soft tissue structures surrounding the shoulder joints present without abnormalities.

SEX

FS

The elbow joints bilaterally present smooth osseous margins and no abnormalities of the surrounding soft tissue structures are appreciated.

The osseous and surrounding soft issue structures of the antebrachium bilaterally are within normal limits.

AGE

10 Years

COMPUTED TOMOGRAPHIC DIAGNOSIS

- Mild degenerative osteoarthritis left shoulder joint

INTERPRETED BY

Sebastian Schaub, DVM
Dr. med. vet. DipECVDI

INTERPRETATION OF THE FINDINGS & FURTHER RECOMMENDATIONS

No abnormalities of the front limbs are appreciated in the current CT study of the front limbs, but a prominent subcutaneous fat depot at the cranioventral aspect of the manubrium sterni. The soft tissue structures surrounding the front limbs and of the axillary region bilaterally appear symmetric.

HOSPITAL NAME

Animal Surgical
Center

REFERRING VET

Heal VH

INVOICE

54831

DATE

10-27-22



PATIENT

Annie Matros

SPECIES

Canine

BREED

Wheaten Terrier

SEX

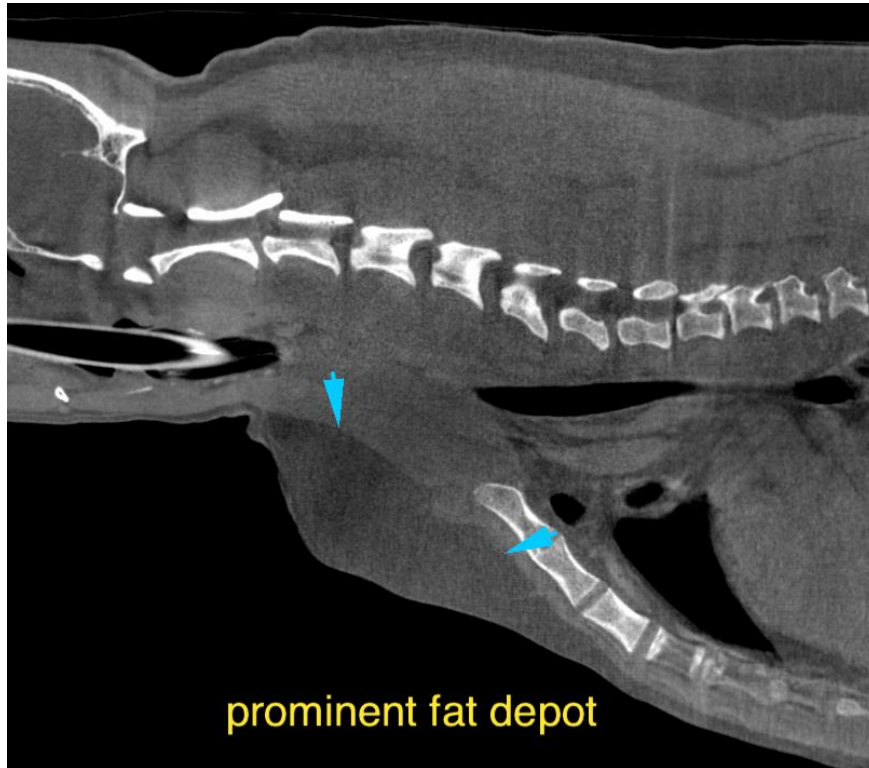
FS

AGE

10 Years

INTERPRETED BY

Sebastian Schaub, DVM
Dr. med. vet. DipECVDI



HOSPITAL NAME

Animal Surgical
Center

REFERRING VET

Heal VH

INVOICE

54831

DATE

10-27-22

The information and recommendations provided are based on the images presented by the referring veterinarian/sonographer. No evaluation can be communicated regarding pathology that was not visible in the image/video clips provided.

Thank you for this referral. If the clinical or image interpretation does not parallel your findings or if I can be of any further assistance please contact me.

Sebastian Schaub, Sebastian Schaub, DVM, Dr. med. vet. DipECVDI
sebast.schaub@gmail.com