



PATIENT

Sophie Byron

PRESENTING CLINICAL SIGNS

Previous history of ear infections. Also previous complaint of neck/back pain.

SPECIES

Canine

COMPUTED TOMOGRAPHY OF THE SKULL AND ENTIRE SPINE

A high resolution plain CT study of the skull and entire spine are provided for review.

BREED

Shih Tzu

Skull

The tooth elements 107, 205, 207, 303, 305, 311, 403 and 405 are absent.

SEX

Female Spayed

The nasal cavity presents the expected aerated spaces between thin & even conchae and turbinates with smooth mucosal lining.

Both temporomandibular joints present congruent joint spaces with even subchondral bone surfaces and are considered within normal limits.

AGE

8 Years

Both tympanic bullae are aerated, the mucosal lining is not seen, the bony wall is smooth and thin. The left external ear canal presents a mild to moderate thickening of the wall and the lumen of the horizontal segment of the left external ear canal is mildly narrowed. A mild amount of soft tissue material is seen within the lumen of the left external ear canal.

INTERPRETED BY

Sebastian Schaub, DVM
Dr. med. vet. DipECVDI

The brain presents no deviation from normal anatomy and symmetry. The brain parenchyma is homogeneous.

The submandibular and medial retropharyngeal lymph nodes are small and elongated with a normal short-to-long-axis-ratio is < 0.5, the attenuation pattern is uniform.

HOSPITAL NAME

State Avenue Vet
Clinic

Spine

The osseous and surrounding soft tissue structures of the cervical spine are within normal limits.

A small punctuate mineralization is seen in the intervertebral disc space T11/T12.

REFERRING VET

Dr. Raul Casas-Dolz

No abnormalities of the osseous and soft tissue structures of the lumbar spine are appreciated.

The periarticular bones of the right coxofemoral joint present mild to moderate osteophyte new bone formation.

INVOICE

48031

COMPUTED TOMOGRAPHIC DIAGNOSIS

- Left sided mild otitis externa
- Multiple absent teeth
- Degenerative osteoarthritis right coxofemoral joint
- Chondroid disc degeneration T11/T12
- Normal cervical & lumbar spine

DATE

10-27-21



PATIENT

Sophie Byron

INTERPRETATION OF THE FINDINGS & FURTHER RECOMMENDATIONS

The left sided otitis externa is fitting the history, there is no evidence of accompanying otitis media.

SPECIES

Canine

No abnormalities of the spine are noted, explaining the potential spinal pain. In case of strong clinical suspicion for compressive myelopathy, recommend complementing workup by a post contrast study ± myelographic CT study or MRI study of the spine.

BREED

Shih Tzu

SEX

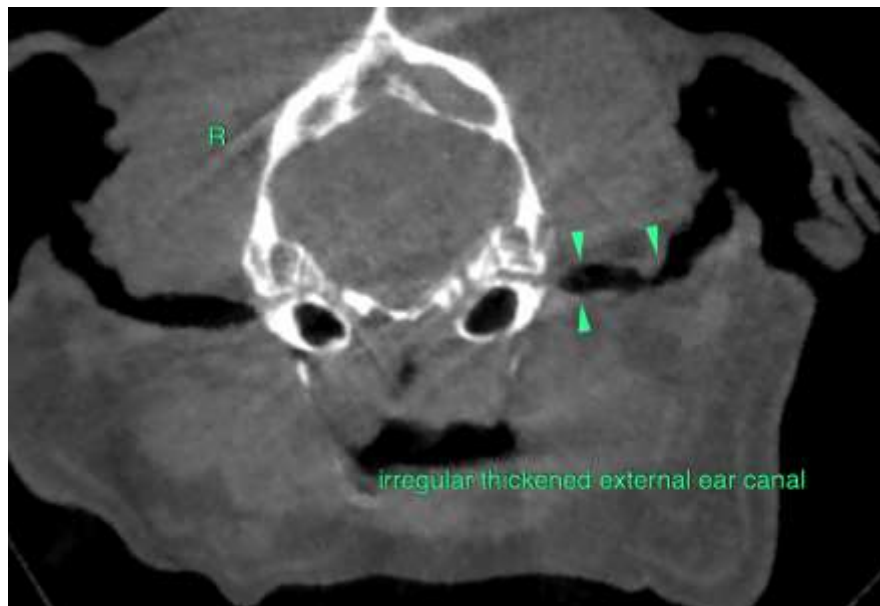
Female Spayed

AGE

8 Years

INTERPRETED BY

Sebastian Schaub, DVM
Dr. med. vet. DipECVDI



HOSPITAL NAME

State Avenue Vet
Clinic

REFERRING VET

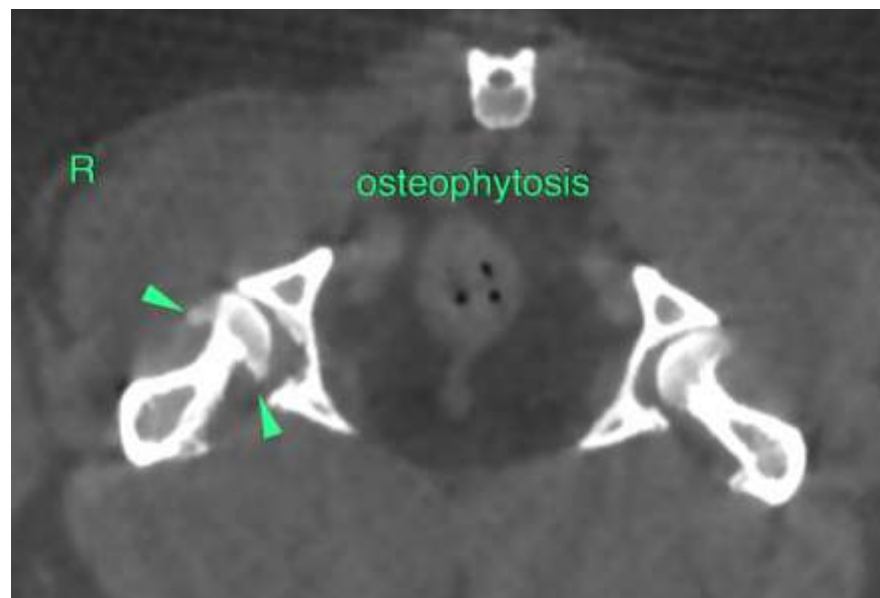
Dr. Raul Casas-Dolz

INVOICE

48031

DATE

10-27-21





PATIENT

Sophie Byron

The information and recommendations provided are based on the images presented by the referring veterinarian. No evaluation can be communicated regarding pathology that was not visible in the image/video clips provided.

SPECIES

Canine

Thank you for this referral. If the clinical or image interpretation does not parallel your findings or if I can be of any further assistance please contact me.

Sebastian Schaub, Sebastian Schaub, DVM, Dr. med. vet. DipECVDI
sebast.schaub@gmail.com

BREED

Shih Tzu

SEX

Female Spayed

AGE

8 Years

INTERPRETED BY

Sebastian Schaub, DVM
Dr. med. vet. DipECVDI

HOSPITAL NAME

State Avenue Vet
Clinic

REFERRING VET

Dr. Raul Casas-Dolz

INVOICE

48031

DATE

10-27-21