



PATIENT

Finnegan Price

PRESENTING CLINICAL SIGNS

Patient presented for licking on left pelvic limb forepaw region, owner states started on Sunday, history of breaking left hind digit 4, p2 ~ 6 months ago. Deep pyoderma present

SPECIES

Canine

RADIOGRAPHIC STUDY OF THE LEFT TARSAL JOINT

Radiographs of the left tarsal joint/hind paw in two imaging planes are provided for review.

BREED

Goldendoodle

RADIOGRAPHIC FINDINGS

A homogeneous moderate soft tissue swelling is present along the dorsal aspect of the tarsal joint and metatarsal region. The middle phalanx of the fourth digit presents mild abaxial bending and a widened diaphysis. The remainder of the osseous structures of the tarsal joint and left hind paw are within normal limits.

SEX

MN

RADIOGRAPHIC DIAGNOSIS

- Soft tissue swelling left hind paw/tarsal region
- History of fractured middle phalanx fourth digit left hind limb – fracture is in the remodeling phase.

AGE

1.7 Years

INTERPRETATION OF THE FINDINGS & FURTHER RECOMMENDATIONS

The soft tissue swelling of the left hind paw/tarsal region is not specific and is likely a sequela to the described pyoderma. Trauma or unlikely neoplasia are considerations as well.

INTERPRETED BY

Sebastian Schaub, DVM
Dr. med. vet. DipECVDI

HOSPITAL NAME

Boca Park Animal
Hospital

REFERRING VET

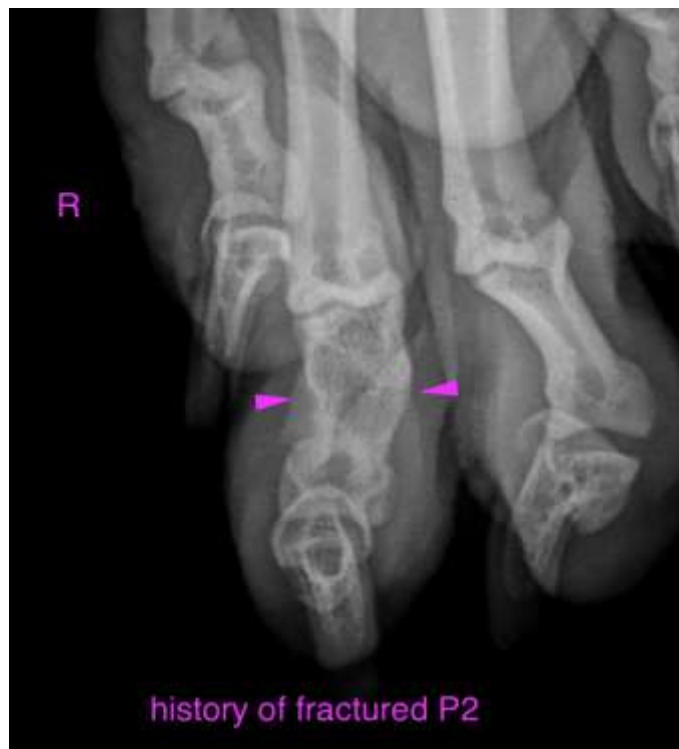Dr. Corinna Gorgon

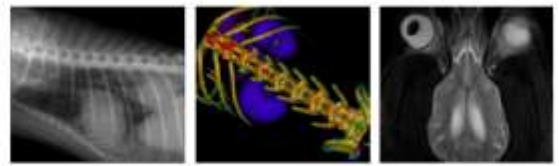
INVOICE

48037

DATE

10-27-21





PATIENT

Finnegan Price

SPECIES

Canine

BREED

Goldendoodle

SEX

MN

AGE

1.7 Years

INTERPRETED BY

Sebastian Schaub, DVM
Dr. med. vet. DipECVDI

HOSPITAL NAME

Boca Park Animal
Hospital

REFERRING VET

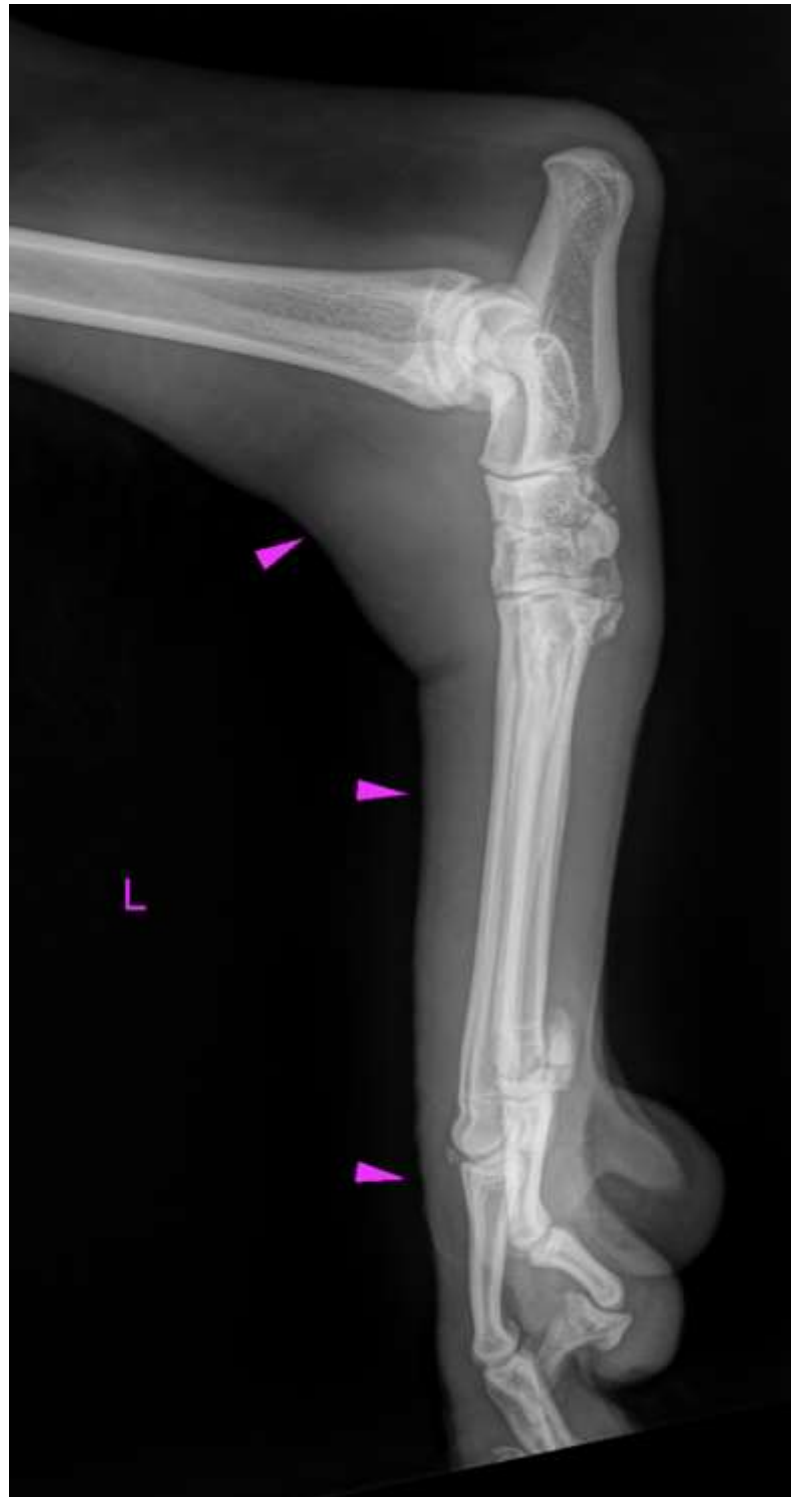Dr. Corinna Gorgon

INVOICE

48037

DATE

10-27-21





PATIENT

Finnegan Price

The information and recommendations provided are based on the images presented by the referring veterinarian. No evaluation can be communicated regarding pathology that was not visible in the image/video clips provided.

SPECIES

Canine

Thank you for this referral. If the clinical or image interpretation does not parallel your findings or if I can be of any further assistance please contact me.

Sebastian Schaub, Sebastian Schaub, DVM, Dr. med. vet. DipECVDI
sebast.schaub@gmail.com

BREED

Goldendoodle

SEX

MN

AGE

1.7 Years

INTERPRETED BY

Sebastian Schaub, DVM
Dr. med. vet. DipECVDI

HOSPITAL NAME

Boca Park Animal
Hospital

REFERRING VET

Dr. Corinna Gorgon

INVOICE

48037

DATE

10-27-21