
PATIENT PRESENTING CLINICAL SIGNS

Romeo Moran Vomiting for the last 36 hours, lethargic. Bringing up bile mostly, has vomited 2-3 times. Indoor cat Doesn't have access to strings, bands, elastics

SPECIES Abnormal PE/Chem/CBC/UA Results: CBC, chemistry all WNL SNAP fPL Normal

Feline **RADIOGRAPHIC STUDY OF THE ABDOMEN**

Radiographs of the thorax in three imaging planes are provided for review.

BREED RADIOGRAPHIC FINDINGS

Siamese The surrounding bony structures are within normal limits.

SEX A significant subcutaneous swelling is seen along the dorsal aspect of the spine with multiple small, interspersed gas bubbles – consistent with preceding subcutaneous infusion.

Neutered Male The serosal detail is maintained throughout the peritoneal and retroperitoneal space.

AGE The liver is appropriate in position, size and presents uniform opacity.

2 Years The splenic head is in the anticipated position and within normal limits for size and opacity.

Both kidneys are seen and present with normal size, shape, delineation, and opacity. The urinary bladder is in its anticipated position. No radiopaque calculi are noted throughout the upper and lower urinary tract.

INTERPRETED BY

Sebastian Schaub, DVM Dr. med. vet. The stomach is in its anticipated position and empty.

DipECVDI The small intestinal loops are of even diameter and non-dilated, a small amount of gas is seen within the small intestinal loops and considered within normal limits.

HOSPITAL NAME

Balmy Beach Pet Hospital The colon is seen in the expected position and presents with appropriate content.

RADIOGRAPHIC DIAGNOSIS

- Empty stomach

REFERRING VET

Dr. Singh

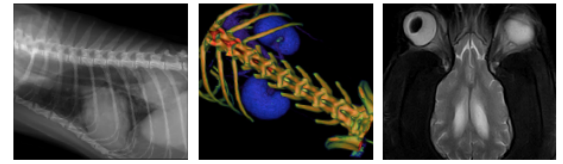
INTERPRETATION OF THE FINDINGS & FURTHER RECOMMENDATIONS
INVOICE

42431

The radiographic study of the abdomen presents without abnormalities, explaining the presenting clinical signs. There is no evidence of radiopaque foreign material or signs for gastrointestinal mechanical obstruction. If clinical signs are refractory to therapy, recommend follow up radiographs or a complete abdominal ultrasound examination; in some cases, a high ileus may lack classical radiographic signs of mechanical obstruction.

DATE

10/26/22



PATIENT

Romeo Moran

The information and recommendations provided are based on the images presented by the referring veterinarian. No evaluation can be communicated regarding pathology that was not visible in the image/video clips provided.

SPECIES

Feline

Thank you for this referral. If the clinical or image interpretation does not parallel your findings or if I can be of any further assistance please contact me.

BREED

Siamese

Sebastian Schaub, Sebastian Schaub, DVM, Dr. med. vet. DipECVDI
sebast.schaub@gmail.com

SEX

Neutered Male

AGE

2 Years

INTERPRETED BY

Sebastian Schaub,
DVM Dr. med. vet.
DipECVDI

HOSPITAL NAME

Balmy Beach Pet
Hospital

REFERRING VET

Dr. Singh

INVOICE

42431

DATE

10/26/22