


PATIENT PRESENTING CLINICAL SIGNS

Sweet Pea Forrest Stray dog hit by a car 3 weeks ago. Pain in jaw when eating and eye. Enucleation is planned for tomorrow morning.

SPECIES COMPUTED TOMOGRAPHY OF THE SKULL

Canine A high resolution pre- and post-contrast CT study of the skull is provided for review.

COMPUTED TOMOGRAPHIC FINDINGS

BREED The pictured parts of the dentition are complete. Triadan 401 presents a moderate periapical widening of the periodontal space.

Mixed The left maxillary bone presents with a horizontal fissure line, running in a rostrocaudal direction, proximal to the alveolar crests of the left maxillary bone. The fissure line is extending into the rostral aspect of the left zygomatic bone.

SEX A short oblique fissure line is seen running through the sphenoid bone.

Female The zygomatic process of the left temporal bone presents a sagittal fracture in the most lateral aspect of the mandibular fossa with two isolated osseous fragments, measuring up to 3.8 mm in size. A short fissure line is running through the ventral tip of the retroarticular process of the left temporomandibular joint.

AGE 4 Years The left ocular bulb is collapsed and has an irregular shape. There is a defect of the perpendicular plate of the left palatine bone with perforation of the nasal cavity and focal intranasal soft tissue swelling

Mild destruction of the nasal conchal & turbinate structures is noted.

INTERPRETED BY

Sebastian Schaub, DVM
 Dr. med. vet. DipECVDI

Distal to the left paracondylar process of the occipital bone, an isolated osseous fragment is seen.

Both tympanic bullae are aerated, the mucosal lining is not seen, the bony wall is smooth and thin. The external ear canals are within normal limits.

HOSPITAL NAME

Mobile Pet Imaging
 CFL

The brain presents no deviation from normal anatomy and symmetry. The brain parenchyma is homogeneous and within normal limits for attenuation and distribution of contrast enhancement. The ventricular system is non-dilated and symmetric.

The submandibular and medial retropharyngeal lymph nodes are small and elongated with a normal short-to-long-axis-ratio is < 0.5, the attenuation and contrast enhancement pattern is uniform.

REFERRING VET

Meaux

COMPUTED TOMOGRAPHIC DIAGNOSIS
INVOICE

54793

- History of blunt craniofacial trauma with secondary laceration of the left ocular bulb
- Chronic traumatic closed articular fracture left zygomatic process of the left temporal bone
- Multiple non-displaced chronic traumatic fissure lines along the osseous structures of the viscerocranium and the sphenoid bone
- Chronic traumatic fractured left paracondylar process occipital bone
- Mild nasal conchal destruction – suspect secondary to trauma
- Tooth root granuloma 401

DATE

10-25-22



PATIENT INTERPRETATION OF THE FINDINGS & FURTHER RECOMMENDATIONS

Sweet Pea Forrest

The findings are fitting the history of craniofacial trauma with laceration of the left ocular bulb and multiple non-displaced fractures of the viscerocranium, skull base and an articular fracture of the left temporomandibular joint. Enucleation of the left ocular bulb is already scheduled. Conservative management of the fractures is the therapy of choice.

SPECIES

Canine

BREED

Mixed

SEX

Female

AGE

4 Years

INTERPRETED BY

Sebastian Schaub, DVM
Dr. med. vet. DipECVDI

HOSPITAL NAME

Mobile Pet Imaging
CFL

REFERRING VET

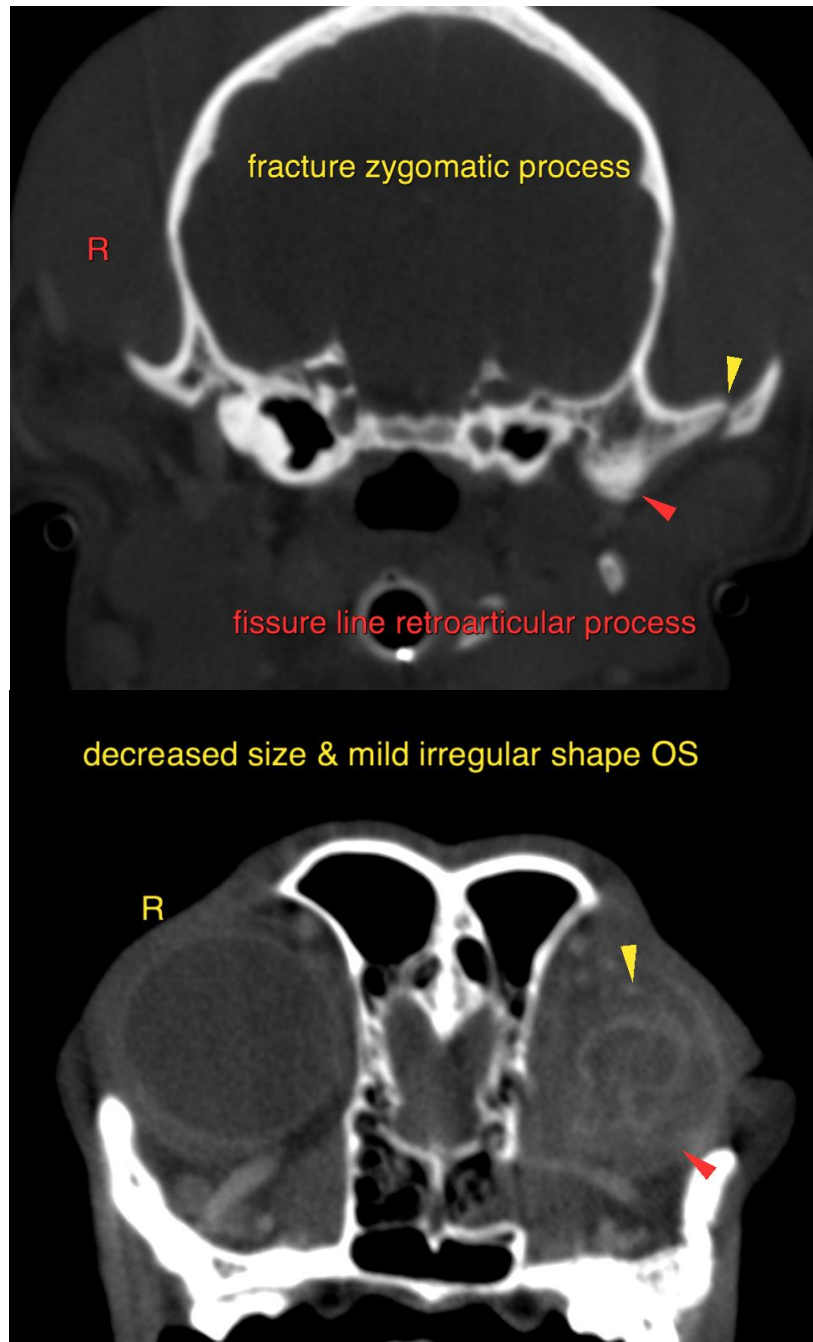
Meaux

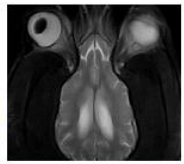
INVOICE

54793

DATE

10-25-22





PATIENT

Sweet Pea Forrest

SPECIES

Canine

BREED

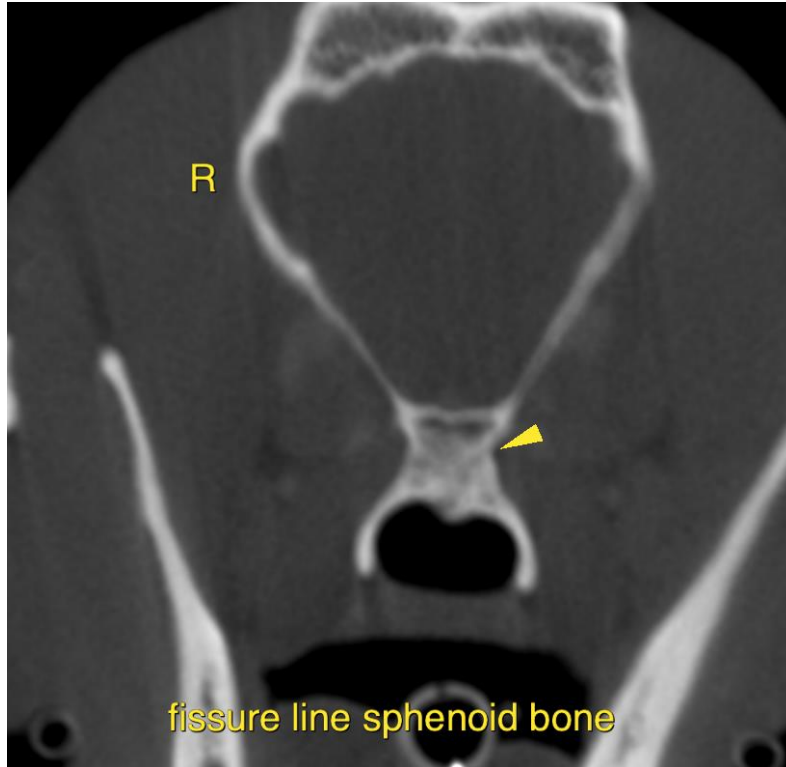
Mixed

SEX

Female

AGE

4 Years



INTERPRETED BY

Sebastian Schaub, DVM
Dr. med. vet. DipECVDI

HOSPITAL NAME

Mobile Pet Imaging
CFL

REFERRING VET

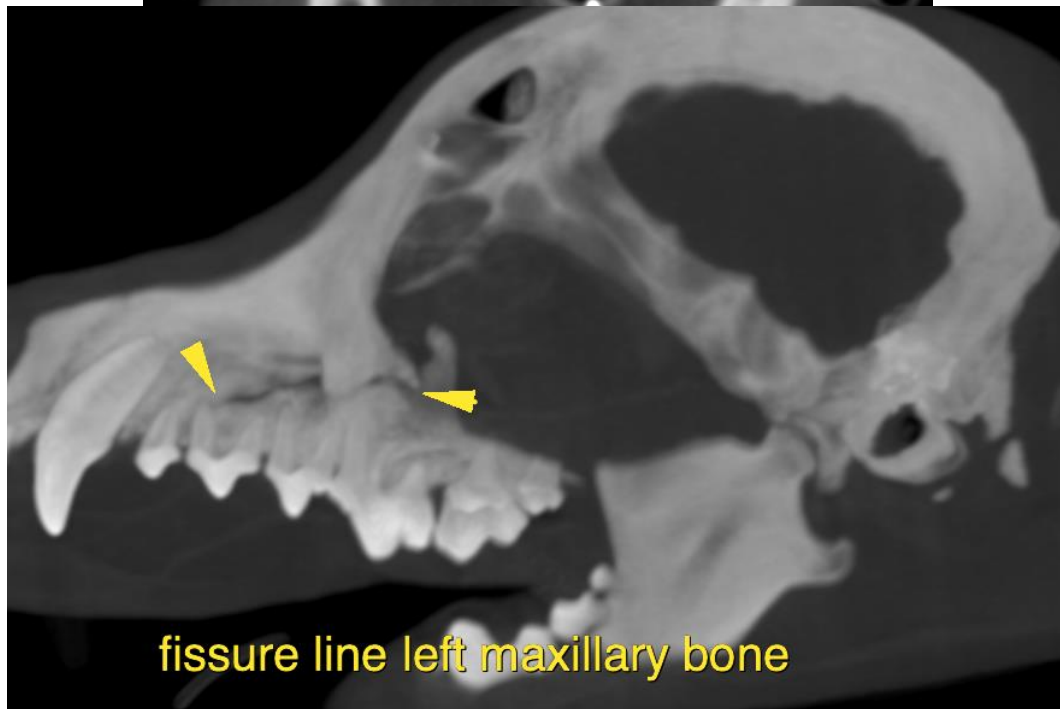
Meaux

INVOICE

54793

DATE

10-25-22





PATIENT

Sweet Pea Forrest

The information and recommendations provided are based on the images presented by the referring veterinarian/sonographer. No evaluation can be communicated regarding pathology that was not visible in the image/video clips provided.

SPECIES

Canine

Thank you for this referral. If the clinical or image interpretation does not parallel your findings or if I can be of any further assistance please contact me.

BREED

Mixed

Sebastian Schaub, Sebastian Schaub, DVM, Dr. med. vet. DipECVDI
sebast.schaub@gmail.com

SEX

Female

AGE

4 Years

INTERPRETED BY

Sebastian Schaub, DVM
Dr. med. vet. DipECVDI

HOSPITAL NAME

Mobile Pet Imaging
CFL

REFERRING VET

Meaux

INVOICE

54793

DATE

10-25-22