



PATIENT

Sophia Schmidt

PRESENTING CLINICAL SIGNS

Front limb lameness intermittently for past 2 months. Improves on Rimadyl but worsens again when discontinued.

SPECIES

Canine

RADIOGRAPHIC STUDY OF THE SHOULDER JOINTS

Radiographs of the shoulder joints in a mediolateral projection are provided for review.

BREED

Lab X

RADIOGRAPHIC FINDINGS

The proximal metaphysis of the left humerus presents an ill-defined zone with permeative osteolytic lesions and mild immature periosteal new bone formation at the caudal aspect.

The osseous and soft tissue structures of the right shoulder joint are within normal limits.

A well-defined roundish mineralized body is superimposed on the caudal aspect of the neck.

SEX

Female

RADIOGRAPHIC DIAGNOSIS

- Monostotic aggressive osteolytic lesion left proximal humerus
- Dystrophic mineralization caudal aspect of the neck

AGE

10 Years

INTERPRETATION OF THE FINDINGS & FURTHER RECOMMENDATIONS

The aggressive osseous lesion of the left proximal humerus is highly suggestive for primary osseous neoplasia – such as osteosarcoma, chondrosarcoma, fibrosarcoma, hemangiosarcoma, other. FNA sampling ± bone biopsy might be used to confirm the diagnosis.

Consider full tumor staging.

INTERPRETED BY

Sebastian Schaub, DVM
Dr. med. vet. DipECVDI

HOSPITAL NAME

Gentle Doctor Animal
Hospital

REFERRING VET

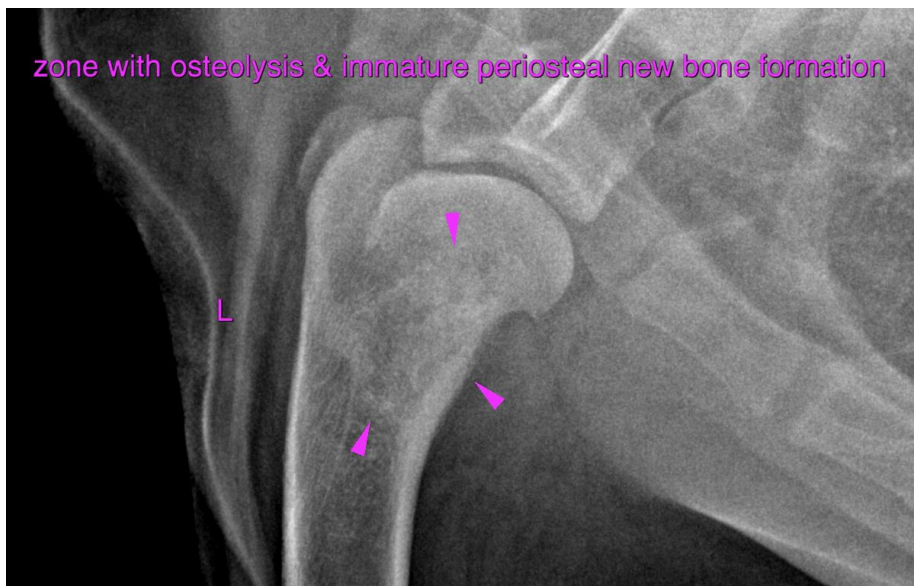
Sydney Thorson

INVOICE

54807

DATE

10-25-22





PATIENT

Sophia Schmidt

SPECIES

Canine

The information and recommendations provided are based on the images presented by the referring veterinarian/sonographer. No evaluation can be communicated regarding pathology that was not visible in the image/video clips provided.

BREED

Lab X

Thank you for this referral. If the clinical or image interpretation does not parallel your findings or if I can be of any further assistance please contact me.

Sebastian Schaub, Sebastian Schaub, DVM, Dr. med. vet. DipECVDI
sebast.schaub@gmail.com

SEX

Female

AGE

10 Years

INTERPRETED BY

Sebastian Schaub, DVM
Dr. med. vet. DipECVDI

HOSPITAL NAME

Gentle Doctor Animal
Hospital

REFERRING VET

Sydney Thorson

INVOICE

54807

DATE

10-25-22