



PATIENT PRESENTING CLINICAL SIGNS

PATIENT
Ozzy Fuellgraf

SPECIES
Canine

BREED
White Shepard

SEX
Male

AGE
4

INTERPRETED BY
Sebastian Schaub, DVM
Dr. med. vet. DipECVDI

HOSPITAL NAME
Cranberry Holistic
Pet Care

REFERRING VET
Cynthia Maro

INVOICE
54819

DATE
10-25-22

Pet jumped out of a 2nd story window 09/04/2022; owner took pet to emergency clinic that diagnosed carpal hyper extension of the right carpus with no fracture. Owner noted 2 days after noticed a red area with a small wound behind the paw pad on the right paw, owner stated pet landed on a stick when the incident occurred.
Abnormal PE/Chem/CBC/UA Results:

COMPUTED TOMOGRAPHY OF THE RIGHT CARPAL JOINT

A high resolution plain CT study of the right carpal joint is provided for review.

COMPUTED TOMOGRAPHIC FINDINGS

The right carpal joint presents with a moderate periarticular soft tissue swelling. The periarticular bones of the carpal joint present smooth osseous margins.

The proximal segment of the metacarpal bones presents signs mild solid periosteal new bone formation and multiple submillimeter osseous fragments are seen between the metacarpal bones. At the axial aspect of the fifth metacarpal bone, an isolated fusiform shaped osseous fragment is seen, measuring 4.5 x 1.8 x 11 mm in size.

COMPUTED TOMOGRAPHIC DIAGNOSIS

- History of right carpal hyperextension syndrome
- Articular swelling right carpal joint
- Small osseous fragments between the proximal aspect of the right metacarpal bones

INTERPRETATION OF THE FINDINGS & FURTHER RECOMMENDATIONS

The appreciated changes are consistent with the history of right carpal hyperextension syndrome with multiple small osseous fragments originating from the metacarpal bones and secondary mild chronic osseous remodeling of the affected osseous structures. Further definition of the instability of the carpal joint warrants stressed radiographs under general anesthesia. No clinically relevant fracture is appreciated. Depending on the presenting clinical signs, surgical management – arthrodesis of the carpal joint – appears as the therapy of choice.



PATIENT

Ozzy Fuellgraf

SPECIES

Canine

BREED

White Shepard

SEX

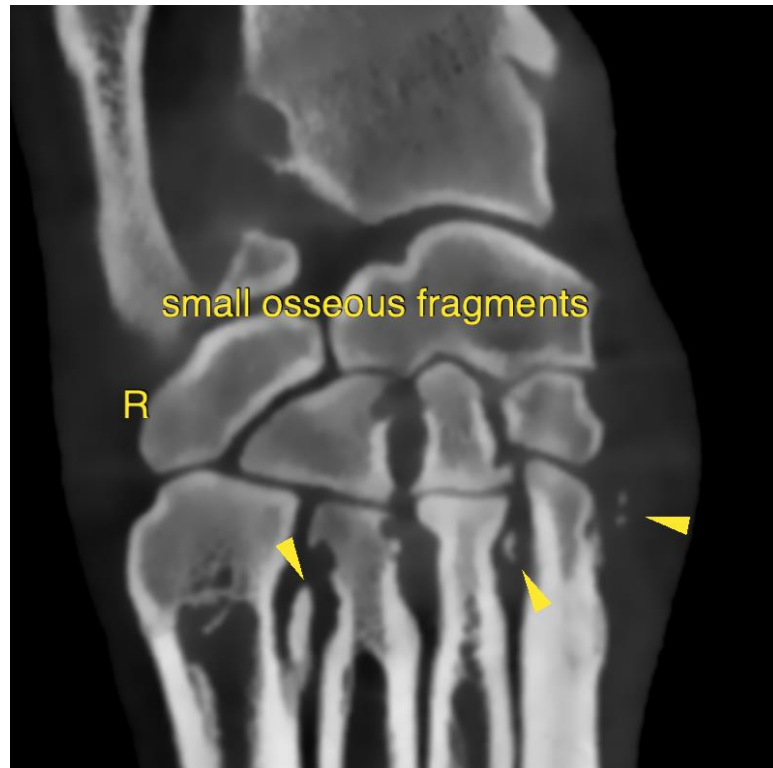
Male

AGE

4

INTERPRETED BY

Sebastian Schaub, DVM
Dr. med. vet. DipECVDI



HOSPITAL NAME

Cranberry Holistic
Pet Care

REFERRING VET

Cynthia Maro

INVOICE

54819

DATE

10-25-22

The information and recommendations provided are based on the images presented by the referring veterinarian/sonographer. No evaluation can be communicated regarding pathology that was not visible in the image/video clips provided.

Thank you for this referral. If the clinical or image interpretation does not parallel your findings or if I can be of any further assistance please contact me.

Sebastian Schaub, Sebastian Schaub, DVM, Dr. med. vet. DipECVDI
sebast.schaub@gmail.com