



**PATIENT PRESENTING CLINICAL SIGNS**

Mr. Flabberson Brown  
 Gastric wall mass, Hx of vomiting and weight loss.  
 Abnormal PE/Chem/CBC/UA Results: Cytology revealed epithelial proliferation

**COMPUTED TOMOGRAPHY OF THE ABDOMEN**

**SPECIES** A high resolution pre- and post-contrast CT study of the is provided for review.

Feline **COMPUTED TOMOGRAPHIC FINDINGS**

A moderate amount of gravity dependent, fluid attenuating material is seen in the peritoneal cavity. The peritoneal fat presents a mild to moderate soft tissue striation. Multiple soft tissue attenuating and mild contrast enhancing nodular lesions are seen throughout the peritoneal cavity.

**BREED**

American Short Hair Both kidneys present within normal limits for size, shape and organ architecture. After contrast administration a bilaterally symmetric and uniform nephro- and pyelogram is noted. In the cranioventral aspect of the urinary bladder, multiple small (<1mm) mineral attenuating calculi are visible.

**SEX**

Neutered Male The adrenal glands are within normal limits for size, shape and organ architecture.

**AGE**

13 Years Both liver and spleen present with normal shape, even surface, uniformly attenuating parenchyma and homogeneous contrast enhancement, unremarkable.  
 The common bile duct is mildly dilated, measuring 3 mm in diameter.

**INTERPRETED BY**

Sebastian Schaub, DVM Dr. med. vet. DipECVDI The ventral half of the fundus of the stomach presents multinodular mural thickening of the wall, measuring up to 2.2 cm in width; post contrast administration the wall layering of the respective segment of the stomach is lost.

**HOSPITAL NAME**

Mobile Pet Imaging The bony and surrounding soft tissue structures reveal no abnormalities.

**REFERRING VET**

Meaux

**COMPUTED TOMOGRAPHIC DIAGNOSIS**

- Intramural gastric mass
- Multiple soft tissue nodules throughout the peritoneal cavity
- Moderate peritoneal effusion
- Mild cystolithiasis

**INTERPRETATION OF THE FINDINGS & FURTHER RECOMMENDATIONS**

**INVOICE**

54799

The mural gastric mass is consistent with primary hepatic neoplasia and given the disseminated nodular lesions throughout the peritoneal cavity, the odds for gastric adenocarcinoma with peritoneal metastatic spread are considered high. Lymphosarcoma, leiomyosarcoma are common differentials as well. Secondary paraneoplastic peritoneal effusion.

**DATE**

10-25-22

FNA sampling of the gastric mass can be used for further differentiation. Due to the peritoneal metastasis, treatment options are limited to palliative management of the patient.



**PATIENT**

Mr. Flabberson  
Brown

**SPECIES**

Feline

**BREED**

American Short Hair

**SEX**

Neutered Male

**AGE**

13 Years

**INTERPRETED BY**

Sebastian Schaub, DVM  
Dr. med. vet. DipECVDI

**HOSPITAL NAME**

Mobile Pet Imaging

**REFERRING VET**

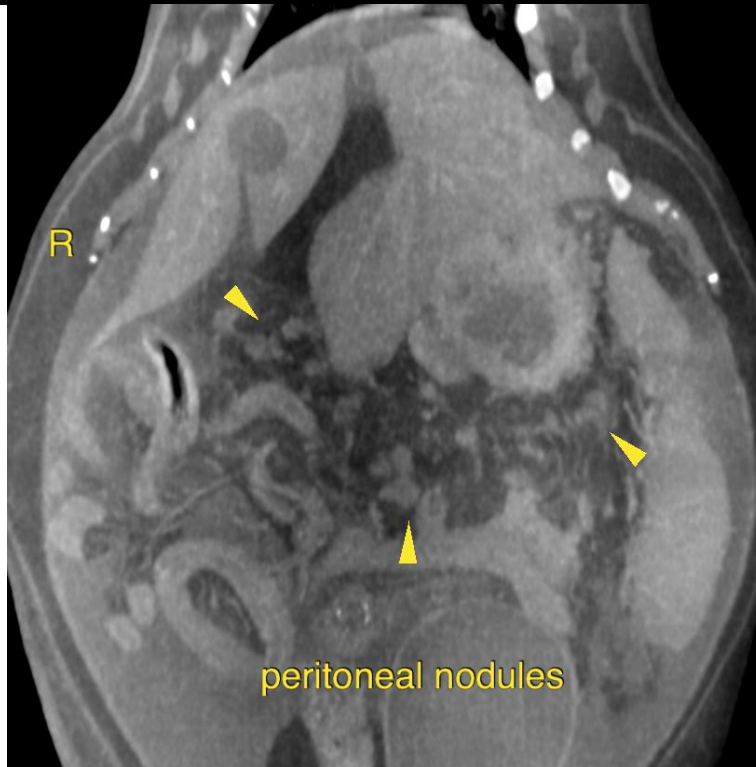
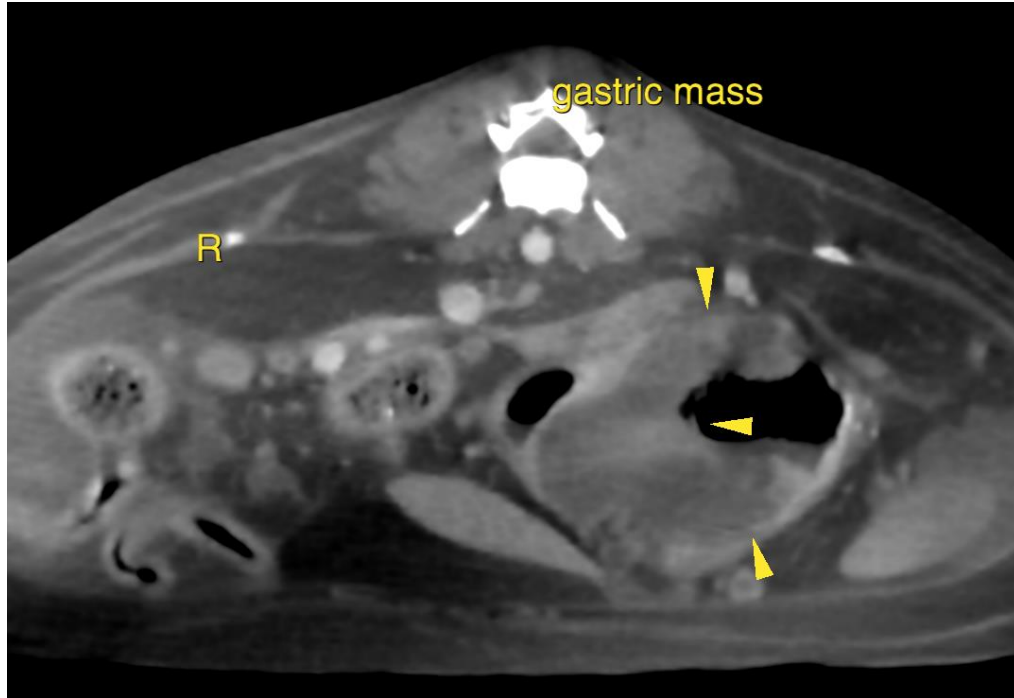
Meaux

**INVOICE**

54799

**DATE**

10-25-22



**PATIENT**

Mr. Flabberson  
Brown

**SPECIES**

Feline

The information and recommendations provided are based on the images presented by the referring veterinarian/sonographer. No evaluation can be communicated regarding pathology that was not visible in the image/video clips provided.

**BREED**

American Short Hair

Thank you for this referral. If the clinical or image interpretation does not parallel your findings or if I can be of any further assistance please contact me.

**Sebastian Schaub**, Sebastian Schaub, DVM, Dr. med. vet. DipECVDI  
sebast.schaub@gmail.com

**SEX**

Neutered Male

**AGE**

13 Years

**INTERPRETED BY**

Sebastian Schaub, DVM  
Dr. med. vet. DipECVDI

**HOSPITAL NAME**

Mobile Pet Imaging

**REFERRING VET**

Meaux

**INVOICE**

54799

**DATE**

10-25-22