

**PATIENT PRESENTING CLINICAL SIGNS**

Little Girl Ferris Gallop rhythm noted today prior to euthanasia. Hx of chronic otitis, painful eating, steady weight loss.

COMPUTED TOMOGRAPHY OF THE SKULL

SPECIES A high resolution plain CT study of the skull is provided for review.

Feline **COMPUTED TOMOGRAPHIC FINDINGS**

Triadan 201, 206 and 407 are absent.

BREED Mild destruction of the right nasal conchal & turbinate structures is appreciated, and a small amount of soft tissue material is attached to the mucosal lining. The right frontal sinus contains a small amount of gravity dependent, soft tissue material and mild hyperostosis of the osseous lining of the right frontal sinus is appreciated.

DSH

SEX Both temporomandibular joints present congruent joint spaces with even subchondral bone surfaces and are considered within normal limits.

Spayed Female

Both tympanic bullae are aerated, the mucosal lining is not seen, the bony wall is smooth and thin. The external ear canals are within normal limits.

AGE The brain presents no deviation from normal anatomy and symmetry. The ventricular system is non-dilated and symmetric.

12 Years

The submandibular and medial retropharyngeal lymph nodes are small and elongated with a normal short-to-long-axis-ratio is < 0.5, the attenuation pattern is uniform.

INTERPRETED BY COMPUTED TOMOGRAPHIC DIAGNOSIS

Sebastian Schaub, DVM
Dr. med. vet. DipECVDI

- Right sided mild destructive rhinitis and sinusitis with mild hyperostosis of the osseous lining
- Multiple absent teeth

HOSPITAL NAME

Mobile Pet Imaging
CFL

INTERPRETATION OF THE FINDINGS & FURTHER RECOMMENDATIONS

The findings are consistent with chronic inflammatory rhinitis and emerging destruction of the nasal turbinate structures. Primary viral rhinitis ± bacterial superinfection is most likely.

No additional abnormalities are appreciated, explaining the weight loss or pain during mastication.

REFERRING VET

Meaux

INVOICE

54802

DATE

10-25-22



PATIENT

Little Girl Ferris

SPECIES

Feline

BREED

DSH

SEX

Spayed Female

AGE

12 Years

INTERPRETED BY

Sebastian Schaub, DVM
Dr. med. vet. DipECVDI

HOSPITAL NAME

Mobile Pet Imaging
CFL

REFERRING VET

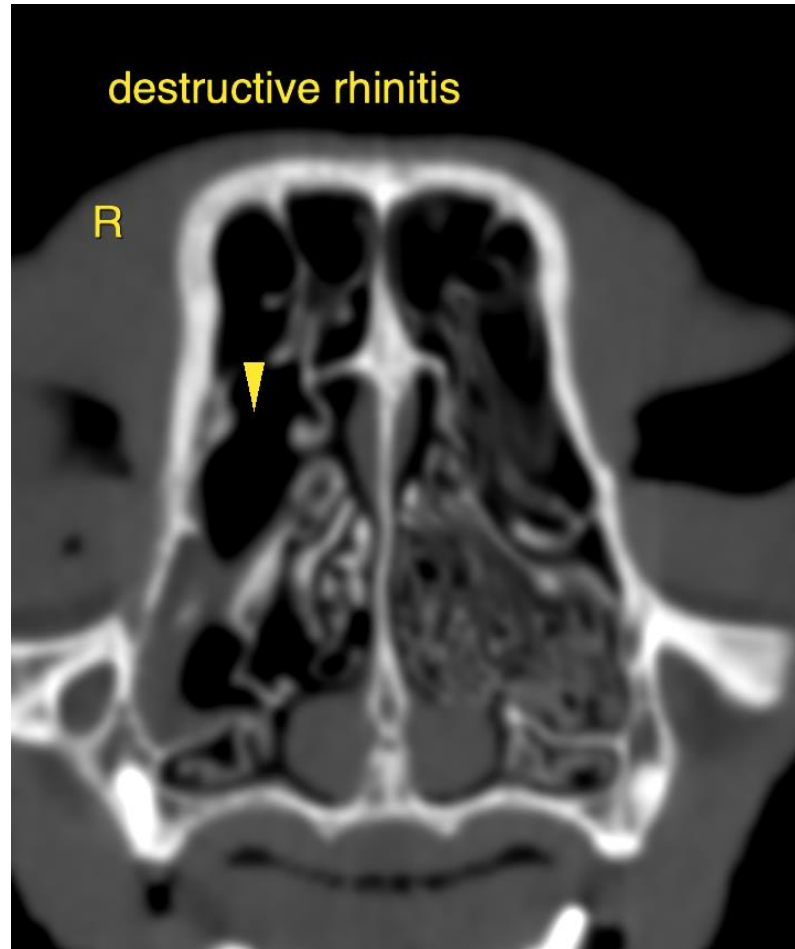
Meaux

INVOICE

54802

DATE

10-25-22



The information and recommendations provided are based on the images presented by the referring veterinarian/sonographer. No evaluation can be communicated regarding pathology that was not visible in the image/video clips provided.

Thank you for this referral. If the clinical or image interpretation does not parallel your findings or if I can be of any further assistance please contact me.

Sebastian Schaub, Sebastian Schaub, DVM, Dr. med. vet. DipECVDI
sebast.schaub@gmail.com