



**PATIENT PRESENTING CLINICAL SIGNS**

Zodiark Johnson History: Vomiting and not eating since Friday, Ingested Styrofoam  
Abnormal PE/Chem/CBC/UA Results: Elevated bilirubin

**SPECIES RADIOGRAPHIC STUDY OF THE ABDOMEN**

Feline Radiographs of the abdomen in three imaging planes are provided for review.

**RADIOGRAPHIC FINDINGS**

**BREED**

DSH The surrounding bony structures are within normal limits.

No abnormalities of the extraabdominal soft tissues are noted. The abdominal wall is smooth and thin.

**SEX**

The serosal detail is maintained throughout the peritoneal and retroperitoneal space.

Neutered Male

The liver is appropriate in position, size and presents uniform opacity.

**AGE**

The splenic head is in the anticipated position and within normal limits for size and opacity.

2 Years

Both kidneys are seen and present with normal size, shape, delineation and opacity. The urinary bladder is in its anticipated position. No radiopaque calculi are noted throughout the upper and lower urinary tract.

**INTERPRETED BY**

The stomach is in its anticipated position and empty but a very mild amount of gas.

Sebastian Schaub,  
DVM Dr. med. vet.  
DipECVDI

The small intestinal loops are generalized mildly to moderately distended by gas and present mild scalloping pattern of the wall.

**HOSPITAL NAME**

The colon is seen in the expected position and presents with appropriate content.

St. Catharine's AH

**RADIOGRAPHIC DIAGNOSIS**

- Gas pattern intestinal tract

**REFERRING VET**

Dr. Boctor

**INTERPRETATION OF THE FINDINGS & FURTHER RECOMMENDATIONS**

The gas pattern of the intestinal tract can be secondary to stress, enteritis, (sub)ileus. There is no evidence of radiopaque foreign material or atypically shaped radiolucent structures throughout the intestinal tract. However, if clinical signs are refractory to empirical therapy, consider follow up radiographs or an abdominal ultrasound examination.

**INVOICE**

14017

**DATE**

10/25/21



**PATIENT**

Zodiark Johnson

**SPECIES**

Feline

**BREED**

DSH

**SEX**

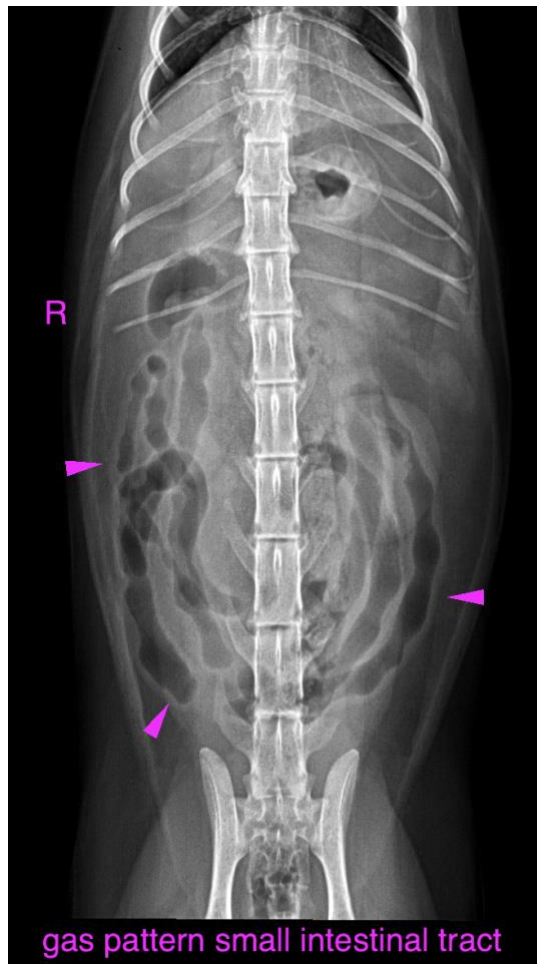
Neutered Male

**AGE**

2 Years

**INTERPRETED BY**

Sebastian Schaub,  
DVM Dr. med. vet.  
DipECVDI



**HOSPITAL NAME**

St. Catharine's AH

The information and recommendations provided are based on the images presented by the referring veterinarian. No evaluation can be communicated regarding pathology that was not visible in the image/video clips provided.

**REFERRING VET**

Dr. Boctor

Thank you for this referral. If the clinical or image interpretation does not parallel your findings or if I can be of any further assistance please contact me.

**Sebastian Schaub**, Sebastian Schaub, DVM, Dr. med. vet. DipECVDI  
sebast.schaub@gmail.com

**INVOICE**

14017

**DATE**

10/25/21



**PATIENT**

Zodiark Johnson

**SPECIES**

Feline

**BREED**

DSH

**SEX**

Neutered Male

**AGE**

2 Years

**INTERPRETED BY**

Sebastian Schaub,  
DVM Dr. med. vet.  
DipECVDI

**HOSPITAL NAME**

St. Catharine's AH

**REFERRING VET**

Dr. Boctor

**INVOICE**

14017

**DATE**

10/25/21