



PATIENT

Erin Couitis

PRESENTING CLINICAL SIGNS

R/O FB vs pyometra vs gastritis vs other Vomiting excessively whenever the dog drinks any water, immediate vomiting. Last oral intake - yesterday 5:00 pm. Vomited 1x yesterday, and 7-8 times today. Licking vulva excessively, last heat was May 2022 B/W done two weeks and all WNL

SPECIES

Canine

RADIOGRAPHIC STUDY OF THE ABDOMEN

Radiographs of the abdomen in three imaging planes are provided for review.

BREED

Golden Retriever

RADIOGRAPHIC FINDINGS

The surrounding bony structures are within normal limits.

No abnormalities of the extraabdominal soft tissues are noted. The abdominal wall is smooth and thin.

SEX

Female

The serosal detail is maintained throughout the peritoneal and retroperitoneal space.

The liver is appropriate in position, size and presents uniform opacity.

The splenic head is in the anticipated position and within normal limits for size and opacity. The splenic body and tail are considered normal for position, size, shape and opacity.

AGE

3 Years

Both kidneys are seen and present with normal size, shape, delineation and opacity. The urinary bladder is in its anticipated position. No radiopaque calculi are noted throughout the upper and lower urinary tract.

INTERPRETED BY

Sebastian Schaub, DVM
Dr. med. vet. DipECVDI

The stomach is in its anticipated position and is empty

The small intestinal loops are of even diameter and non-dilated, a small amount of gas is seen within the small intestinal loops and considered within normal limits.

HOSPITAL NAME

Truscott Animal
Hospital

The colon is seen in the expected position and presents with appropriate content. The cecum is moderately distended by gas.

RADIOGRAPHIC DIAGNOSIS

- Empty stomach

REFERRING VET

Dr. Medhat Meawad

INTERPRETATION OF THE FINDINGS & FURTHER RECOMMENDATIONS

The radiographic study presents without abnormalities, explaining the vomiting. There is no evidence of radiopaque foreign material or signs for gastrointestinal mechanical obstruction. The uterus is not visible in the current radiographic study. The presumptive diagnosis is gastritis. If clinical signs are refractory to therapy, recommend follow up radiographs or a complete abdominal ultrasound examination; in some cases, a high ileus may lack classical radiographic signs of mechanical obstruction.

INVOICE

54772

DATE

10-24-22



PATIENT

Erin Couitis

SPECIES

Canine

BREED

Golden Retriever

SEX

Female

AGE

3 Years

INTERPRETED BY

Sebastian Schaub, DVM
Dr. med. vet. DipECVDI

HOSPITAL NAME

Truscott Animal
Hospital

REFERRING VET

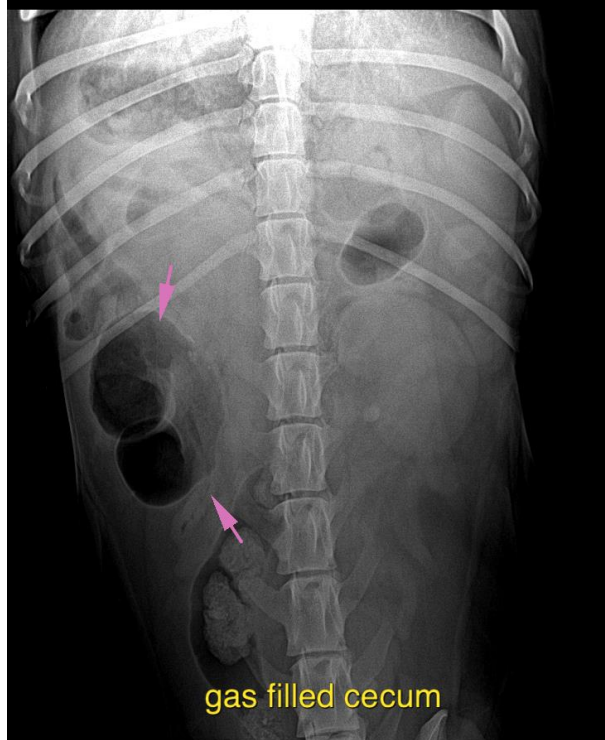
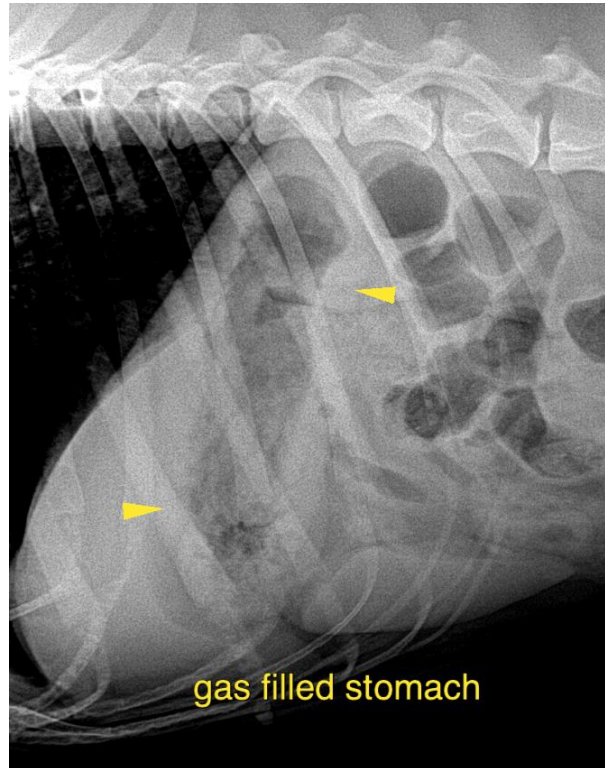
Dr. Medhat Meawad

INVOICE

54772

DATE

10-24-22





PATIENT

Erin Couitis

The information and recommendations provided are based on the images presented by the referring veterinarian/sonographer. No evaluation can be communicated regarding pathology that was not visible in the image/video clips provided.

SPECIES

Canine

Thank you for this referral. If the clinical or image interpretation does not parallel your findings or if I can be of any further assistance please contact me.

BREED

Golden Retriever

Sebastian Schaub, Sebastian Schaub, DVM, Dr. med. vet. DipECVDI
sebast.schaub@gmail.com

SEX

Female

AGE

3 Years

INTERPRETED BY

Sebastian Schaub, DVM
Dr. med. vet. DipECVDI

HOSPITAL NAME

Truscott Animal
Hospital

REFERRING VET

Dr. Medhat Meawad

INVOICE

54772

DATE

10-24-22