



PATIENT PRESENTING CLINICAL SIGNS

Molly Goggans History: Suspected ectopic ureter. Dribbles urine constantly.

Abnormal PE/Chem/CBC/UA Results:

SPECIES

Canine

COMPUTED TOMOGRAPHIC STUDY OF THE ABDOMEN

A high resolution pre- and post-contrast CT study of the abdomen is provided for review.

BREED

Poodle Mix

COMPUTED TOMOGRAPHIC FINDINGS

The serosal fat presents normal attenuation behavior. There is no evidence of peritoneal effusion or peritonitis.

SEX

Intact Female

Both kidneys present within normal limits for size, shape and organ architecture. After contrast administration a bilaterally symmetric and uniform nephro- and pyelogram is noted. The left ureter enters the urinary bladder wall approximately 3.5 mm cranial to the vesicourethral junction. The right ureter enters the wall of the urethra approximately level with the vesicourethral junction and presents a potential intramural course within the urethral wall over approximately 1.1 cm.

AGE

11 Weeks 5 Days

The adrenal glands are within normal limits for size, shape and organ architecture.

Both liver and spleen present with normal shape, even surface, uniformly attenuating parenchyma and homogeneous contrast enhancement, unremarkable.

INTERPRETED BY

Sebastian Schaub,
DVM Dr. med. vet.
DipECVDI

The portal vein presents a normal order of its tributary veins and intrahepatic branching. No abnormal vessel is noted inside and outside of the liver parenchyma.

The pancreas is evenly contoured, the pancreatic parenchyma is homogeneous and presents uniform contrast enhancement.

HOSPITAL NAME

Neel VH

The position, delineation, wall and content of the gastrointestinal tract are considered within normal limits throughout.

REFERRING VET

Dr. Britney Daily

The growth plates are age related open.

COMPUTED TOMOGRAPHIC DIAGNOSIS

- Right sided ureteral ectopia
- Caudal position of the left vesicoureteral orifice level with the urinary bladder neck

INVOICE

14016

INTERPRETATION OF THE FINDINGS & FURTHER RECOMMENDATIONS

DATE

10/23/21



PATIENT

Molly Goggans

The findings are consistent with right sided ureteral ectopia and caudal termination of the left ureter into the urinary bladder. The findings explain the described clinical signs. Consider bilateral neoureterostomy.

SPECIES

Canine

BREED

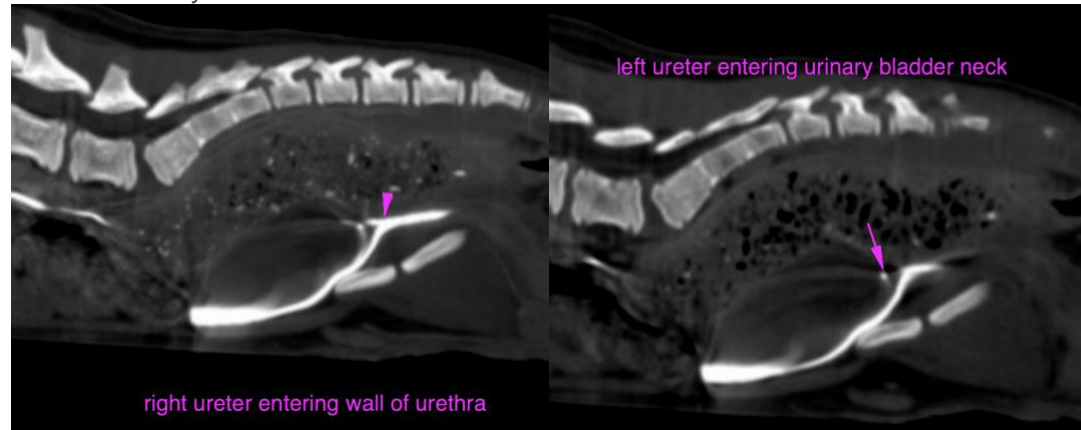
Poodle Mix

SEX

Intact Female

AGE

11 Weeks 5 Days



The information and recommendations provided are based on the images presented by the referring veterinarian. No evaluation can be communicated regarding pathology that was not visible in the image/video clips provided.

Thank you for this referral. If the clinical or image interpretation does not parallel your findings or if I can be of any further assistance please contact me.

INTERPRETED BY

Sebastian Schaub, Sebastian Schaub, DVM, Dr. med. vet. DipECVDI
sebast.schaub@gmail.com

Sebastian Schaub,
DVM Dr. med. vet.
DipECVDI

HOSPITAL NAME

Neel VH

REFERRING VET

Dr. Britney Daily

INVOICE

14016

DATE

10/23/21