**DATE PRESENTING CLINICAL SIGNS**

10-23-21 Coughing, hacking and making honking sound. Currently on cough tablets 1 tab PO tid.

PATIENT RADIOGRAPHIC STUDY OF THE THORAX

Lilo Martin Radiographs of the thorax in three imaging planes are provided for review.

RADIOGRAPHIC FINDINGS**SPECIES**

Canine

The sternum presents moderate degenerative changes. Mild osteophyte new bone formation is seen at the caudal aspect of the humeral heads bilaterally.

The extrathoracic soft tissues present homogeneous without abnormalities.

BREED

Border Collie Mix

The heart is of normal size and shape, there is no evidence of cardiac chamber or vascular enlargement. The pulmonary vasculature is within normal limits.

SEX

Female Spayed

The cranial mediastinum presents the expected soft tissue opacity. The mediastinal width is less than twice the width of the vertebral column at the same level.

The trachea is normal in diameter and presents the anticipated course. The luminal outline of the trachea is smooth.

AGE

5/10/2007

There is a roundish, homogeneous soft tissue opaque mass visible within the parenchyma of the left caudal lung lobe, measuring approximately 2.5 intercostal spaces in size. The accompanying bronchi and vessels are displaced by the mass effect.

INTERPRETED BY

Sebastian Schaub,
DVM

Dr. med. vet. DipECVDI

The diaphragm is well delineated with even surface and the expected mild cranial bulging of the diaphragmatic cupola.

The hepatic parenchyma presents moderate branching mineralization.

RADIOGRAPHIC DIAGNOSIS

- Solitary pulmonary mass left caudal lung lobe
- No evidence of pulmonary metastatic disease
- Moderate degenerative changes sternum & costal cartilages
- Suspect incidental mineralization of the intrahepatic biliary vessels

HOSPITAL NAME

Claws n Paws Animal
Hospital

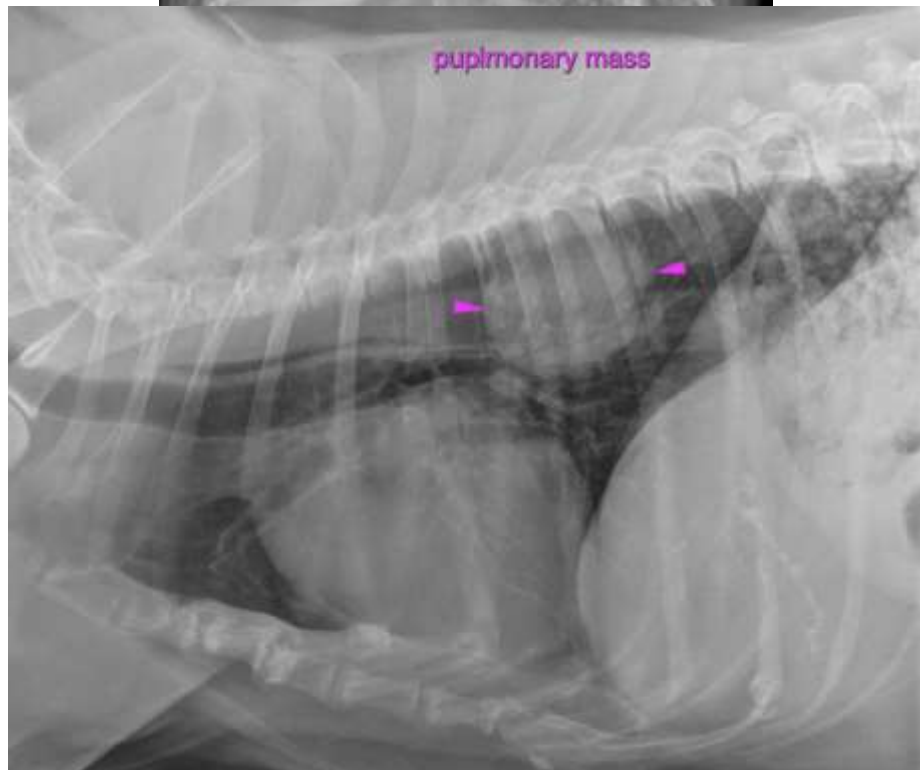
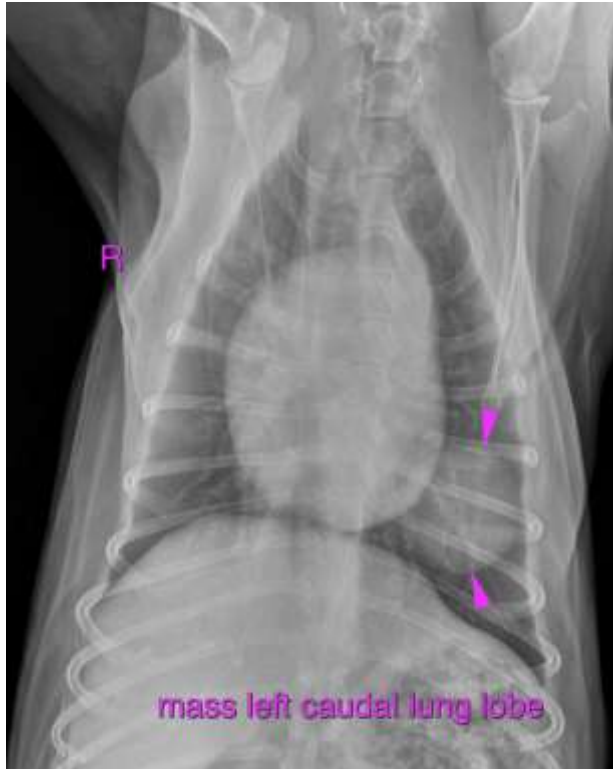INTERPRETATION OF THE FINDINGS & FURTHER RECOMMENDATIONS**REFERRING VET**

Dr. Singh

The pulmonary mass is highly suggestive for primary pulmonary neoplasia – such as bronchogenic carcinoma, bronchoalveolar carcinoma - and can explain the described clinical signs. Granuloma or bronchogenic cyst are potentials but considered less likely. Ultrasound guided FNA sampling of the pulmonary mass can be tried; placing the patient in left lateral recumbency prior to the ultrasound can help to improve visibility of the mass by induction of compression atelectasis of the overlying aerated lung parenchyma.

INVOICE

47947



The information and recommendations provided are based on the images presented by the referring veterinarian. No evaluation can be communicated regarding pathology that was not visible in the image/video clips provided.

Thank you for this referral. If the clinical or image interpretation does not parallel your findings or if I can be of any further assistance please contact me.

Sebastian Schaub, Sebastian Schaub, DVM, Dr. med. vet. DipECVDI
sebast.schaub@gmail.com