



PATIENT PRESENTING CLINICAL SIGNS

Banjo Light
SPECIES Canine
BREED German Shorthaired Pointer

In August 2021, Banjo was playing with another dog. He suddenly presented neck pain. Since then, he cannot turn his head to the left and is whining. He can walk properly but has to have his bowl lifted to eat. He was assessed several times at Georgian Bay Veterinary Hospital. Different medications were tried: myorelaxant (methocarbamol), pain killer (gabapentin), anti-inflammatory (metacam switched to galliprant) without any improvement. He is getting gradually worse. Chiropractor, massage therapist and acupuncture have been performed. Last week, a Quant C6 slightly above the normal range raises a suspicion for Lyme disease and antibiotics (doxycycline) are prescribed. Cervical radiographs did not reveal any visible abnormalities. For the past one year and a half, he has experienced some mild discomfort now and then in the neck. Some whining when standing up for example but he has never affected his quality of life.

Abnormal PE/Chem/CBC/UA Results: Gait/posture: Ambulatory with no ataxia or paresis. Low head carriage. Cannot turn his head to the left, not full to the right. Sensory/nociception: Moderate to severe hyperesthesia elicited with palpation along the cervical vertebral column.

SEX MAGNETIC RESONANCE IMAGING OF THE NECK AND BRACHIAL PLEXUS

MN
 T2&T1 (DIXON) weighted pre- and post-gadolinium sequences in multiple imaging planes are provided for review.

AGE MAGNETIC RESONANCE IMAGING FINDINGS

5 Years
INTERPRETED BY Sebastian Schaub, DVM
 Dr. med. vet. DipECVDI

The intervertebral discs C3/C4, C4/C5 and C6/C7 are mildly protruding into the vertebral canal, distorting the epidural space at the same level. In the left neuroforamen C6/C7 heterogeneous mild hypointense material is visible; the material is occupying approximately 60% of the area of the respective neuroforamen. The left nerve root C7 is thickened and moderate contrast enhancing within the neuroforamen.

The intervertebral discs C2/C3, C5/C6 and C6/C7 present a mild to moderate loss of the in fluid sensitive sequences hyperintense signal of the nucleus pulposus.

HOSPITAL NAME

Animal Health Partners

The epaxial musculature along the caudal segment of the cervical spine presents a mild hyperintense striation in the fluid sensitive sequences with a corresponding contrast enhancement pattern.

The brachial plexus region bilaterally presents without abnormalities.

REFERRING VET

Dr. Marchal

MAGNETIC RESONANCE IMAGING DIAGNOSIS

INVOICE

47951

- Intervertebral disc extrusion C6/C7 into the left neuroforamen with secondary neuroforaminal stenosis
- Secondary neuritis left spinal nerve C7
- Mild edema and stripy contrast enhancement pattern epaxial musculature along caudal cervical spine
- Mild intervertebral disc protrusion C3/C4 and C4/C5 without compressive myelopathy

DATE

10-23-21



PATIENT

Banjo Light

SPECIES

Canine

BREED

German Shorthaired
Pointer

SEX

MN

AGE

5 Years

INTERPRETED BY

Sebastian Schaub, DVM
Dr. med. vet. DipECVDI

HOSPITAL NAME

Animal Health
Partners

REFERRING VET

Dr. Marchal

INVOICE

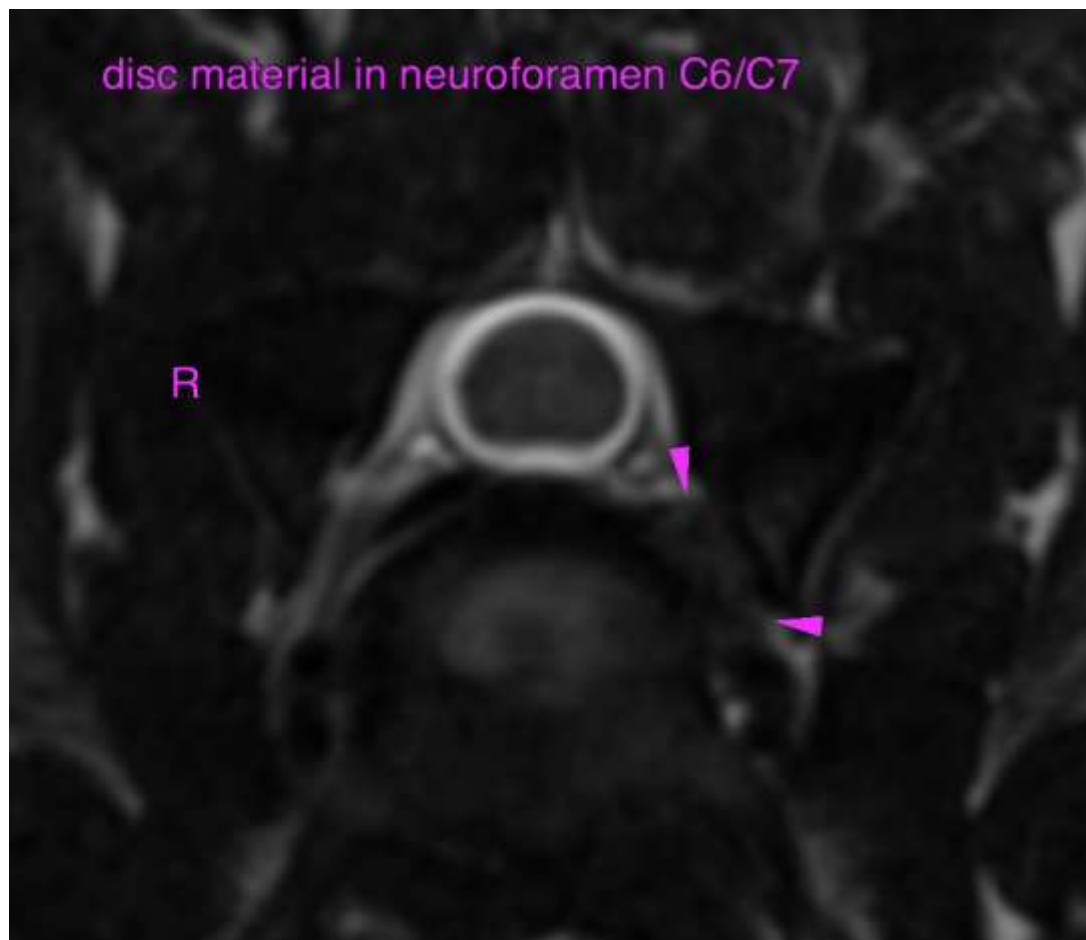
47951

DATE

10-23-21

INTERPRETATION OF THE FINDINGS & FURTHER RECOMMENDATIONS

The left sided intervertebral disc extrusion into the left neuroforamen C6/C7 is a potential explanation for the described clinical signs, and the changes of the musculature at the same level can represent tension of the epaxial musculature at the same level. The chances of surgical decompression versus conservative management – such as local infiltration of glucocorticoid into the neuroforamen – should be discussed with neurologist/surgeon.





PATIENT

Banjo Light

SPECIES

Canine

BREED

German Shorthaired
Pointer

SEX

MN

AGE

5 Years

INTERPRETED BY

Sebastian Schaub, DVM
Dr. med. vet. DipECVDI

HOSPITAL NAME

Animal Health
Partners

REFERRING VET

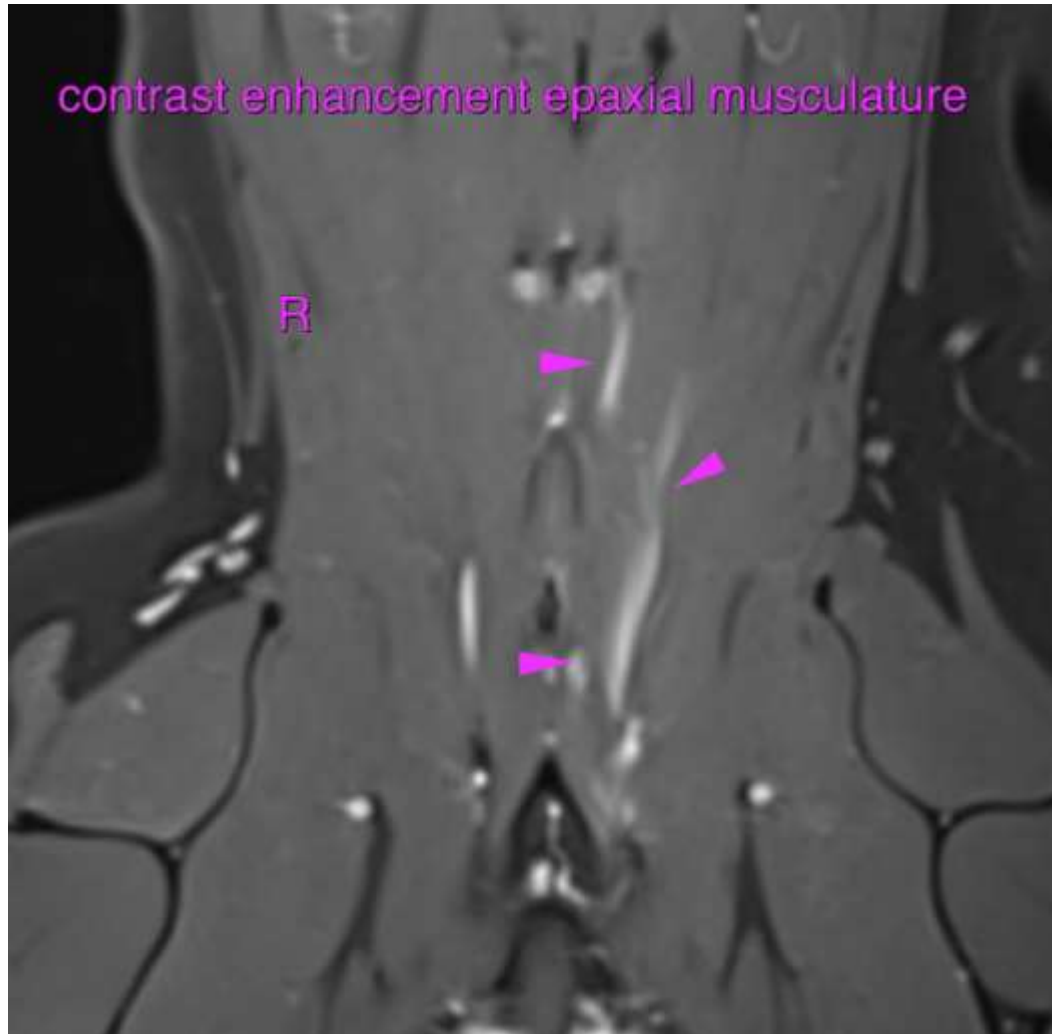Dr. Marchal

INVOICE

47951

DATE

10-23-21



The information and recommendations provided are based on the images presented by the referring veterinarian. No evaluation can be communicated regarding pathology that was not visible in the image/video clips provided.

Thank you for this referral. If the clinical or image interpretation does not parallel your findings or if I can be of any further assistance please contact me.

Sebastian Schaub, Sebastian Schaub, DVM, Dr. med. vet. DipECVDI
sebast.schaub@gmail.com