



PATIENT PRESENTING CLINICAL SIGNS

Suki Rapant
SPECIES
 Canine

History: Patient presenting for surgical consult for Left ear ablation. Chronic ear infections for about 2 years. Ear medications have been prescribed: Oti-Pack Marbofloxacin/Ketoconazole/Triamcinolone. Has seen derm for eyes, diagnosed with bilateral entropion, on cyclosporin. P is on Hydrolyzed protein diet, prior to that was on Purina HA. Previously tested positive for Hookworms- resolved? , history of UTI- resolved? History of luxating patellas. No v/c/d/s, eating and drinking normally, no change in mentation. P is currently on Advantage multi.

BREED
 English Bulldog

Abnormal PE/Chem/CBC/UA Results:

COMPUTED TOMOGRAPHIC STUDY OF THE SKULL

A high resolution pre- and post-contrast CT study of the skull is provided for review.

SEX COMPUTED TOMOGRAPHIC FINDINGS

Spayed Female
AGE
 5 Years

A significant brachygnathia superior is present. Multiple teeth are absent. Triadan 201, 206 and 307 present a moderate widening of the periodontal space.

The nasal cavity presents the expected aerated spaces between thin and even conchae and turbinates with smooth mucosal lining. A mild aberrant caudal conchal growth is visible. The soft palate is moderately thickened.

INTERPRETED BY
 Sebastian Schaub, DVM Dr. med. vet. DipECVDI

Both temporomandibular joints present congruent joint spaces with even subchondral bone surfaces and are considered within normal limits.

HOSPITAL NAME
 Critical Vet Care/Suncoast Veterinary

Both tympanic bullae contain a moderate (R) to marked (L) amount of non-contrast enhancing soft tissue material. The osseous lining of both tympanica bullae is moderately thickened and mildly irregular. The wall of the left external ear canal is markedly thickened and the lumen is completely obliterated by the epithelial lining; marked mineralization of the left external ear canal is noted. The right external ear canal presents a moderate thickening of the wall, and the lumen is moderately narrowed; moderate shell-like mineralization of the wall of the right external ear canal is visible.

The brain presents no deviation from normal anatomy and symmetry. The brain parenchyma is homogeneous and within normal limits for attenuation and distribution of contrast enhancement. The ventricular system is non-dilated and symmetric.

REFERRING VET
 Dr. Young

The left medial retropharyngeal lymph node is prominent, uniform soft tissue attenuating and contrast enhancing; the short-to-long-axis ratio is maintained normal <0.5.

COMPUTED TOMOGRAPHIC DIAGNOSIS

- INVOICE**
 13975
- Bilateral chronic otitis externa, L>>L with dystrophic mineralization of the external ear canal
 - Bilateral chronic otitis media, L>R

DATE
 10/22/21



PATIENT

Suki Rapant

- Periodontal disease 201, 206 and 307
- Lymphadenopathy left medial retropharyngeal lymph node
- Moderate to marked thickening of the soft palate
- Aberrant caudal conchal growth
- Brachyganthia superior

SPECIES

Canine

BREED

English Bulldog

INTERPRETATION OF THE FINDINGS & FURTHER RECOMMENDATIONS

The findings are fitting the history of chronic otitis externa, L>>R, and secondary otitis media. There is no evidence of periauricular abscess formation. A total ear canal ablation has already been scheduled.

Secondary reactive hyperplasia of the left medial retropharyngeal lymph node.

SEX

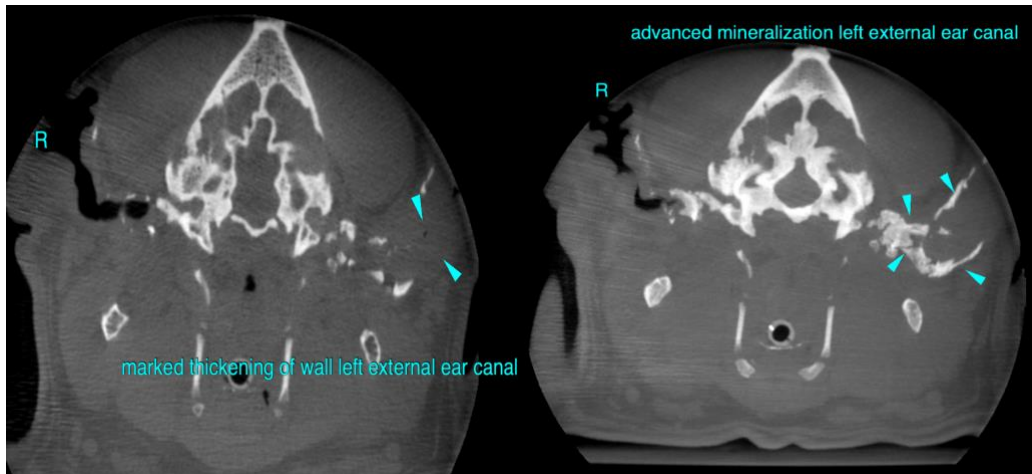
Spayed Female

AGE

5 Years

INTERPRETED BY

Sebastian Schaub,
DVM Dr. med. vet.
DipECVDI



HOSPITAL NAME

Critical Vet
Care/Suncoast
Veterinary

The information and recommendations provided are based on the images presented by the referring veterinarian. No evaluation can be communicated regarding pathology that was not visible in the image/video clips provided.

Thank you for this referral. If the clinical or image interpretation does not parallel your findings or if I can be of any further assistance please contact me.

REFERRING VET

Dr. Young

Sebastian Schaub, Sebastian Schaub, DVM, Dr. med. vet. DipECVDI
sebast.schaub@gmail.com

INVOICE

13975

DATE

10/22/21



PATIENT

Suki Rapant

SPECIES

Canine

BREED

English Bulldog

SEX

Spayed Female

AGE

5 Years

INTERPRETED BY

Sebastian Schaub,
DVM Dr. med. vet.
DipECVDI

HOSPITAL NAME

Critical Vet
Care/Suncoast
Veterinary

REFERRING VET

Dr. Young

INVOICE

13975

DATE

10/22/21