



**PATIENT PRESENTING CLINICAL SIGNS**

**PATIENT** Samantha Casademunt  
**HISTORY:** Presented to ophthalmologist OD: exophthalmia, unable to blink over globe, slightly laterally displaced globe, desiccated dorsal and mid cornea (linear pattern), clear AC, normal iris, clear lens, normal vitreous- posterior globe indented (mass effect); **DIAGNOSES:** Exophthalmia secondary to retrobulbar disease (suspect neoplasia) OD, Superficial Corneal Ulcer OD, Desiccated cornea OD,

**SPECIES** Unable to close eyelids due to exophthalmia OD, Heart Murmur  
 Abnormal PE/Chem/CBC/UA Results:

Feline

**COMPUTED TOMOGRAPHIC STUDY OF THE SKULL**

**BREED** A high resolution pre- and post-contrast CT study of the skull is provided for review.

**DLH COMPUTED TOMOGRAPHIC FINDINGS**

The pictured parts of the dentition are complete and unremarkable in all jaw quadrants.

**SEX**

**SEX** Spayed Female  
 The nasal cavity presents the expected aerated spaces between thin and even conchae and turbinates with smooth mucosal lining.

**AGE**

15 Years

In the caudal aspect of the right orbit, a uniform soft tissue attenuating and heterogeneous contrast enhancing, ill-defined mass is visible measuring approximately 2.3 x 2.4 x 1.5 cm in size. The right ocular bulb is displaced rostrally and laterally by the mass effect. In the lateral aspect the mass in the right orbit is in close contact with the zygomatic arch, no abnormalities of the zygomatic arch are appreciated, the osseous margins are smooth. In the caudal aspect the mass is demarcated by the caudal osseous wall of the right orbit.

**INTERPRETED BY**

Sebastian Schaub,  
 DVM Dr. med. vet.  
 DipECVDI

Both temporomandibular joints present congruent joint spaces with even subchondral bone surfaces and are considered within normal limits.

**HOSPITAL NAME**

Mobile Pet Imaging

A mild amount of gravity dependent, soft tissue attenuating material is visible in the right tympanic bulla. The external ear canals are within normal limits.

The brain presents no deviation from normal anatomy and symmetry. The brain parenchyma is homogeneous and within normal limits for attenuation and distribution of contrast enhancement. The ventricular system is non-dilated and symmetric.

**REFERRING VET**

Meaux

The submandibular and medial retropharyngeal lymph nodes are small and elongated with a normal short-to-long-axis-ratio is < 0.5, the attenuation and contrast enhancement pattern is uniform.

**COMPUTED TOMOGRAPHIC DIAGNOSIS**

**INVOICE**

13983

- Right sided retrobulbar mass
- Secondary right sided exophthalmos

**INTERPRETATION OF THE FINDINGS & FURTHER RECOMMENDATIONS**

**DATE**

10/22/21



**PATIENT**

Samantha Casademunt

The findings support the diagnosis of a right sided retrobulbar soft tissue neoplasia such as sarcoma, melanoma, lymphosarcoma, other. Ultrasound guided FNA sampling by a lateral approach to the orbit can be used as an initial screening tool to determine dignity of the mass. Right sided orbital exenteration appears as a feasible treatment option. Consider full tumor staging.

**SPECIES**

Feline

**BREED**

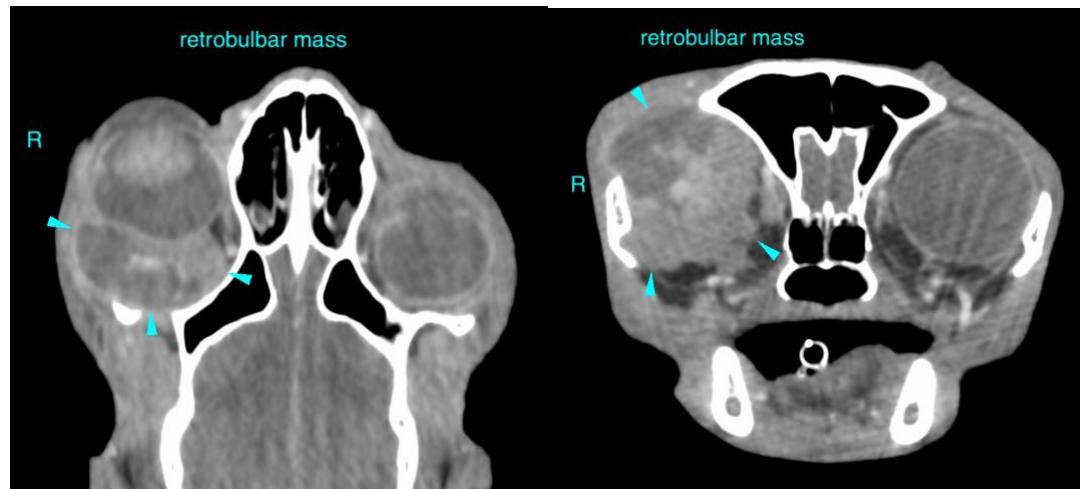
DLH

**SEX**

Spayed Female

**AGE**

15 Years



**The information and recommendations provided are based on the images presented by the referring veterinarian. No evaluation can be communicated regarding pathology that was not visible in the image/video clips provided.**

**INTERPRETED BY**

Sebastian Schaub, DVM Dr. med. vet. DipECVDI

Thank you for this referral. If the clinical or image interpretation does not parallel your findings or if I can be of any further assistance please contact me.

**HOSPITAL NAME**

Mobile Pet Imaging

Sebastian Schaub, Sebastian Schaub, DVM, Dr. med. vet. DipECVDI  
sebast.schaub@gmail.com

**REFERRING VET**

Meaux

**INVOICE**

13983

**DATE**

10/22/21