



**PATIENT PRESENTING CLINICAL SIGNS**

**Lady Gaga Lucero** History: Recent history of increased respiratory noises when sleeping. Minimal to no coughing noted, eating drinking normally. Overweight. PE results revealed normal tracheal palpation, clear mouth and clear lungs. however, a new II/VI murmur was detected with PMI left heart base. 3 views taken for tracheal and thoracic assessment.

**SPECIES**

Canine Abnormal PE/Chem/CBC/UA Results:

**BREED**

Chihuahua

**RADIOGRAPHIC STUDY OF THE THORAX**

Radiographs of the thorax in three imaging planes are provided for review.

**RADIOGRAPHIC FINDINGS**

**SEX**

The body condition score is 8/9.

Spayed Female

The surrounding bony structures are within normal limits.

**AGE**

The extrathoracic soft tissues present homogeneous without abnormalities.

10 Years 7 Months

The heart is of normal size and shape, there is no evidence of cardiac chamber or vascular enlargement. The pulmonary vasculature is within normal limits.

**INTERPRETED BY**

Sebastian Schaub,  
DVM Dr. med. vet.  
DipECVDI

The cranial mediastinum presents the expected soft tissue opacity. The mediastinal width is less than twice the width of the vertebral column at the same level.

**HOSPITAL NAME**

Reid VH

The caudal cervical segment of the trachea is widened in the lateral projections and presents an increased radiopacity – suspect due to positioning with rotation of the trachea.

The bronchial tree presents with thin walls and tapers uniformly towards the periphery as expected. The lung parenchyma presents the expected architecture and opacity; the intrapulmonary vascular branching is seen up to the third order lung vessels.

**REFERRING VET**

Dr. Tim Hazzard

The diaphragm is well delineated with even surface and the expected mild cranial bulging of the diaphragmatic cupola.

**RADIOGRAPHIC DIAGNOSIS**

**INVOICE**

13996

- Obesity
- Otherwise, normal thorax

**INTERPRETATION OF THE FINDINGS & FURTHER RECOMMENDATIONS**

**DATE**

10/22/21

The main finding is the obesity of the patient. The increased respiratory noise might result from pharyngeal collapse and weight control appears beneficial to relieve clinical signs.



**PATIENT**

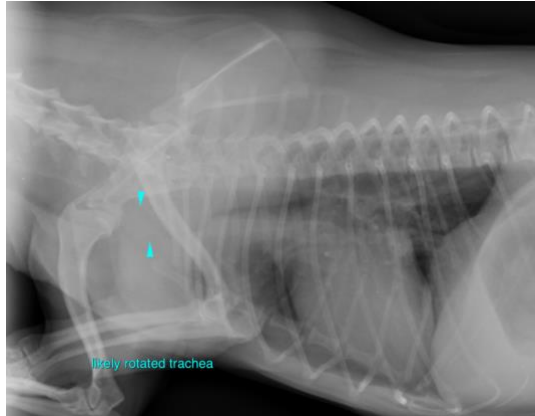
Lady Gaga Lucero

**SPECIES**

Canine

**BREED**

Chihuahua



**SEX**

Spayed Female

**AGE**

10 Years 7 Months

**The information and recommendations provided are based on the images presented by the referring veterinarian. No evaluation can be communicated regarding pathology that was not visible in the image/video clips provided.**

Thank you for this referral. If the clinical or image interpretation does not parallel your findings or if I can be of any further assistance please contact me.

**Sebastian Schaub**, Sebastian Schaub, DVM, Dr. med. vet. DipECVDI  
sebast.schaub@gmail.com

**INTERPRETED BY**

Sebastian Schaub,  
DVM Dr. med. vet.  
DipECVDI

**HOSPITAL NAME**

Reid VH

**REFERRING VET**

Dr. Tim Hazzard

**INVOICE**

13996

**DATE**

10/22/21