

**PATIENT PRESENTING CLINICAL SIGNS**

Cinder Baken Paws History: New kitten to rescue. HX of circling to the left, head tilt to the left. Upper respiratory stidor. Mild nasal and ocular discharge.

SPECIES Abnormal PE/Chem/CBC/UA Results: head tilt to the left, circling to the left. mild ocular and nasal discharge. Severe ear mite discharge, unable to easily visualize TM, inflamed canals. heart and lungs clear other than referred upper respiratory noise. did look under the soft palate and no overt swellings.

Feline

BREED COMPUTED TOMOGRAPHIC STUDY OF THE SKULL

DSH A high-resolution plain CT study of the skull is provided for review.

SEX COMPUTED TOMOGRAPHIC FINDINGS

Male The pictured parts of the dentition are complete and unremarkable in all jaw quadrants.

The nasal cavity presents the expected aerated spaces between thin and even conchae and turbinates with smooth mucosal lining.

AGE

17 Weeks Both tympanica bullae are filled with soft tissue attenuating material and the osseous lining is mildly thickened and smooth. Level with the openings of the auditory tube, the nasopharynx is significantly narrowed. The external ear canals present a moderate irregular epithelial lining and irregular soft tissue material within the lumen of the external ear canals.

INTERPRETED BY

Sebastian Schaub,
DVM Dr. med. vet.
DipECVDI Both temporomandibular joints present congruent joint spaces with even subchondral bone surfaces and are considered within normal limits.

COMPUTED TOMOGRAPHIC DIAGNOSIS**HOSPITAL NAME**

- Bilateral otitis media and externa

State Avenue VC

INTERPRETATION OF THE FINDINGS & FURTHER RECOMMENDATIONS**REFERRING VET**

Dr. Jessica Evoniuk The CT study is consistent with bilateral otitis media and externa – ear mites have already been diagnosed. The otitis media is a plausible explanation for the described clinical signs. At least in the current CT study there is swelling level with the openings of the auditory tubes – clinically no polyp was appreciated.

INVOICE

13943

Regarding the otitis media, a ventral bulla osteotomy might be considered if clinical signs are refractory to conservative empirical management.

DATE

10/21/21



PATIENT

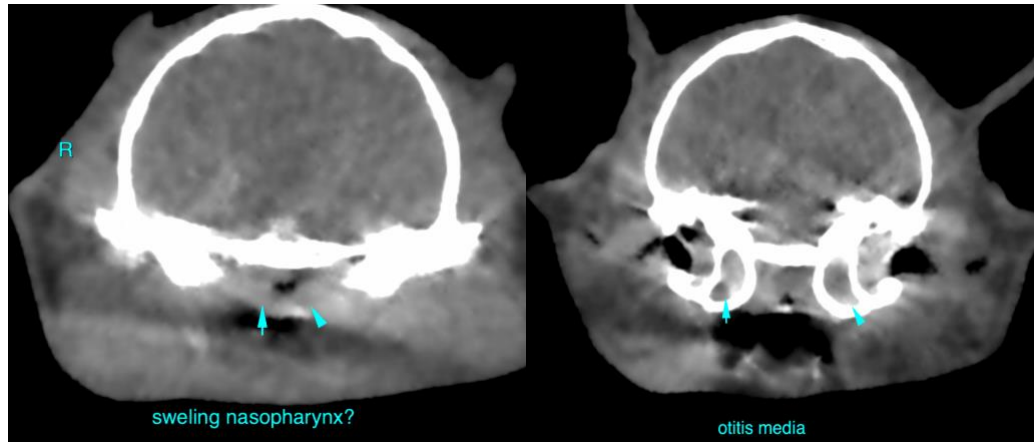
Cinder Baken Paws

SPECIES

Feline

BREED

DSH



SEX

Male

AGE

17 Weeks

The information and recommendations provided are based on the images presented by the referring veterinarian. No evaluation can be communicated regarding pathology that was not visible in the image/video clips provided.

Thank you for this referral. If the clinical or image interpretation does not parallel your findings or if I can be of any further assistance please contact me.

Sebastian Schaub, Sebastian Schaub, DVM, Dr. med. vet. DipECVDI
sebast.schaub@gmail.com

INTERPRETED BY

Sebastian Schaub,
DVM Dr. med. vet.
DipECVDI

HOSPITAL NAME

State Avenue VC

REFERRING VET

Dr. Jessica Evoniuk

INVOICE

13943

DATE

10/21/21