



PATIENT

Chloe Aamodt

PRESENTING CLINICAL SIGNS

Pt presented for trouble walking. O noted pt fell down the stairs a couple weeks ago. Pt already on gabapentin TID and rimadyl BID. Just started up amantadine a couple weeks ago, but o discontinued it after pt fell. On PE: Ataxia on hind limbs, no proprioception bilat hind limbs, has pain sensation, crossed extensor reflex.

SPECIES

Canine

RADIOGRAPHIC STUDY OF THE LUMBAR SPINE AND PELVIS

Radiographs of the lumbar spine and the pelvis in two imaging planes are provided for review.

BREED

Collie Mix

RADIOGRAPHIC FINDINGS

All vertebral endplates of the lumbar spine present mild to moderate spondylosis formation. Convex shaped mineral opaque material is superimposed on the ventral aspect of the vertebral endplate of L2/L3.

SEX

Spayed Female

Very mild step formation is seen between L7/S1.

The osseous and surrounding soft tissue structures of the pelvis are within normal limits. The left coxofemoral joint presents very mild osteophyte formation and a congruent joint space. The periarticular bones of the right coxofemoral joint present mild osteophyte new bone formation.

AGE

14 Years

RADIOGRAPHIC DIAGNOSIS

- Mineralized material superimposed on neuroforamen L2/L3
- Mild step formation L7/S1 – might predispose for lumbosacral stenosis
- Degenerative osteoarthritis right coxofemoral joint, very mild left coxofemoral joint
- Spondylosis deformans along the lumbar spine

INTERPRETED BY

Sebastian Schaub, DVM
Dr. med. vet. DipECVDI

INTERPRETATION OF THE FINDINGS & FURTHER RECOMMENDATIONS

The mineral opaque material superimposed on the neuroforamen L2/L3 is most consistent with lateral spondylosis formation, however protrusion of mineral opaque material is a consideration as well. Cross-sectional imaging can be used for further evaluation of the spine.

The clinical relevance of the degenerative joint disease of the right coxofemoral joint is unclear.

HOSPITAL NAME

The Pet Hospital of
Stratford

REFERRING VET

Dr Robert Bashkin

INVOICE

54747

DATE

10-20-22



PATIENT

Chloe Aamodt

SPECIES

Canine

BREED

Collie Mix

SEX

Spayed Female

AGE

14 Years

INTERPRETED BY

Sebastian Schaub, DVM
Dr. med. vet. DipECVDI

HOSPITAL NAME

The Pet Hospital of
Stratford

REFERRING VET

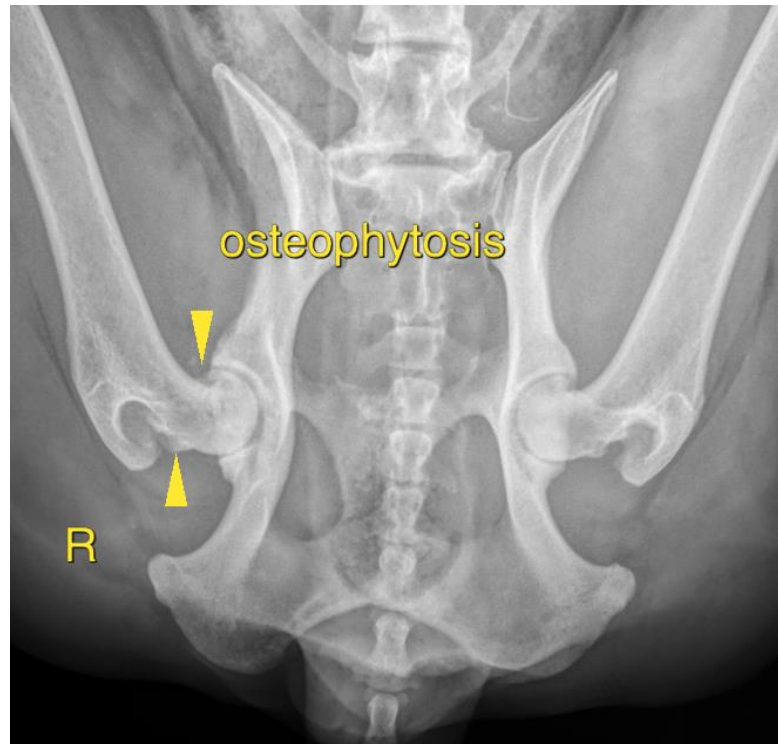
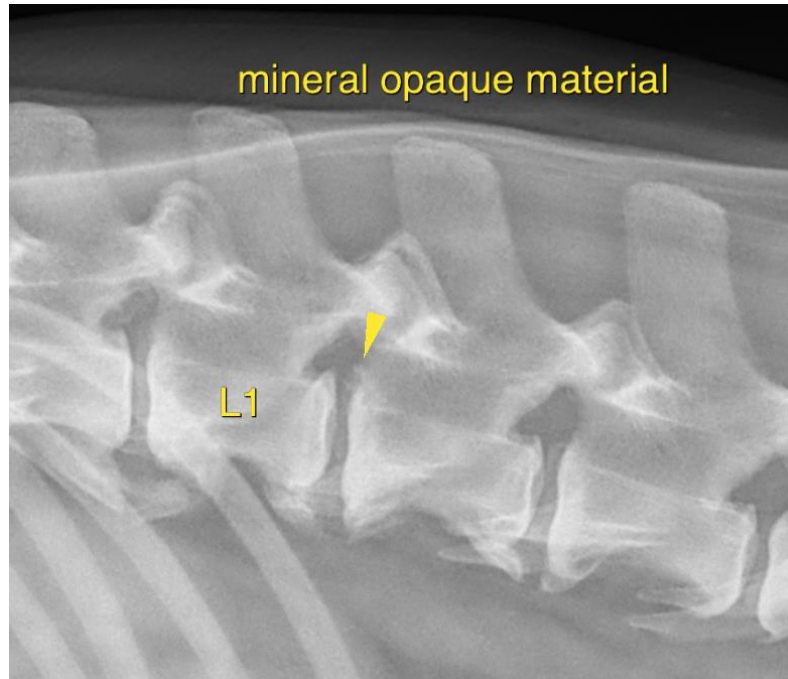
Dr Robert Bashkin

INVOICE

54747

DATE

10-20-22





PATIENT

Chloe Aamodt

The information and recommendations provided are based on the images presented by the referring veterinarian/sonographer. No evaluation can be communicated regarding pathology that was not visible in the image/video clips provided.

SPECIES

Canine

Thank you for this referral. If the clinical or image interpretation does not parallel your findings or if I can be of any further assistance please contact me.

Sebastian Schaub, Sebastian Schaub, DVM, Dr. med. vet. DipECVDI
sebast.schaub@gmail.com

BREED

Collie Mix

SEX

Spayed Female

AGE

14 Years

INTERPRETED BY

Sebastian Schaub, DVM
Dr. med. vet. DipECVDI

HOSPITAL NAME

The Pet Hospital of
Stratford

REFERRING VET

Dr Robert Bashkin

INVOICE

54747

DATE

10-20-22